

Management of chemotherapy extravasation: ESMO–EONS Clinical Practice Guidelines[†]

J. A. Pérez Fidalgo, MD¹, L. García Fabregat, RN¹, A. Cervantes, MD¹, A. Margulies, RN², C. Vidall, RN³ & F. Roila, MD⁴ on behalf of the ESMO Guidelines Working Group*

¹Department of Hematology and Medical Oncology, Institute of Health Research INCLIVA, University of Valencia, Valencia, Spain; ²European Oncology Nursing Society, Zurich, Switzerland; ³Healthcare at Home Ltd, Staffordshire, UK; ⁴Department of Medical Oncology, S. Maria Hospital, Terni, Italy

definitions

Extravasation is the process by which any liquid (fluid or drug) accidentally leaks into the surrounding tissue. In terms of cancer therapy, extravasation refers to the inadvertent infiltration of chemotherapy into the subcutaneous or subdermal tissues surrounding the intravenous or intra-arterial administration site.

Extravasated drugs are classified according to their potential for causing damage as ‘vesicant’, ‘irritant’ and ‘nonvesicant’ (Table 1).

Some vesicant drugs are further classified into two groups: DNA binding and non-DNA binding. Allwood et al. [1] divided the drugs into vesicants, exfoliants, irritants, inflammitants and neutrals.

incidence

Data on the incidence of either extravasation or infiltration are scant due to the absence of a centralized register of chemotherapy extravasation events. Incidence rates vary greatly. Estimates between 0.01% and 7% are noted in various publications [2–7]. Some data suggest that the incidence is decreasing probably due to improvements in the infusion procedure, early recognition of drug leakage and training in management techniques. A single-institution retrospective study confirmed that the overall incidence was 10 times less frequent in 2002 than 15 years earlier (0.01% versus 0.1%; $P = 0.001$) [8]. Data regarding extravasation from central venous access devices (CVAD) are limited.

Table 1. Classification of chemotherapy drugs according to their ability to cause local damage after extravasation

Vesicants	Irritants	Nonvesicants
DNA-binding compounds	Alkylating agents	Arsenic trioxide
Alkylating agents	Carmustine	Asparaginase
Mechlorethamine	Ifosfamide	Bleomycin
Bendamustine ^a	Streptozocin	Bortezomib
Anthracyclines	Dacarbazine	Cladribine
Doxorubicin	Melphalan	Cytarabine
Daunorubicin	Anthracyclines (other):	Etoposide phosphate
Epirubicin	Liposomal doxorubicin	Gemcitabine
Idarubicin	Liposomal	Fludarabine
	Daunorubicin	
Others (antibiotics)	Mitoxantrone	Interferons
Dactinomycin	Topoisomerase II inhibitors	Interleukin-2
Mitomycin C	Etoposide	Methotrexate
Mitoxantrone ^a	Teniposide	Monoclonal antibodies
Non-DNA-binding compounds	Antimetabolites	Pemetrexed
Vinka alkaloids	Fluorouracil	Raltitrexed
Vincristine	Platin salts	Temsirolimus
Vinblastine	Carboplatin	Thiothepa
Vindesine	Cisplatin	Cyclophosphamide
Vinorelbine	Oxaliplatin ^a	
Taxanes	Topoisomerase I inhibitors	
Docetaxel ^a	Irinotecan	
Paclitaxel	Topotecan	
Others	Others	
Trabectedin	Ixabepilone	

^aSingle case reports describe both irritant and vesicant properties.

risk factors for extravasation

Adequate identification of the potential factors for extravasation is important to minimize the risk in some patients. In case of an increased risk of extravasation,

*Correspondence to: ESMO Guidelines Working Group, ESMO Head Office, Via L. Taddei 4, CH-6962 Viganello-Lugano, Switzerland. E-mail: clinicalguidelines@esmo.org and EONS: European Oncology Nursing Society, Avenue E. Mounier 83, B-1200 Brussels, Belgium. E-mail: eons.secretariat@cancernurse.eu

[†]Approved by the ESMO Guidelines Working Group: July 2012. These guidelines were developed by ESMO and EONS and are published simultaneously in *Annals of Oncology* (volume 23, supplement 7) and the *European Journal of Oncology Nursing* (volume 16, issue 5).

Table 2. Patient and procedure-associated risk factors

Patient-related	Cannulation and infusion procedure-related (peripheral or port)
<ul style="list-style-type: none"> • Small and fragile veins • Hard and/or sclerosed veins as a consequence of multiple previous chemotherapy courses or drug abuse • Prominent but mobile veins (e.g. elderly persons) • Known diseases or situations associated with an altered or impaired circulation like Raynaud syndrome, advanced diabetes, severe peripheral vascular disease, lymphedema or superior cava syndrome. • Predisposition to bleeding, increased vascular permeability or those with coagulation abnormalities. • Obesity in which peripheral venous access is more difficult. • Sensory deficits that impair the patient's ability to detect a change in sensation at the site of chemotherapy administration. • Communication difficulties or young children, which hinder the early reporting of the signs and symptoms allowing the identification of extravasation. • Prolonged infusion 	<ul style="list-style-type: none"> • Untrained or inexperienced staff • Multiple attempts at cannulation • Unfavorable cannulation site • Bolus injections • High flow pressure • Choice of equipment (peripheral catheter choice, size, steel 'Butterfly' needle) • Inadequate dressings or poor cannula fixation • Poorly implanted CVAD (too deep for cannula, difficult to secure cannula)

preventive measures should be encouraged or in some cases, insertion of a CVAD should be considered. These factors can be classified under patient-associated and procedure-related risk factors [4, 7, 9].

prevention

Most extravasations can be prevented with the systematic implementation of careful, standardized, evidence-based administration techniques.

In order to minimize the risk of extravasation, the staff involved in the infusion and management of cytotoxic drugs must be trained to implement several preventive protocols [4, 7, 9].

Should an extravasation occur, it is important to remember that the degree of damage is dependent on the type of drug, the drug concentration, the localization of the extravasation and the length of time a drug develops its potential for damage.

Table 3. Preventive protocols to minimize the risk of extravasation

- 'Site of insertion': Identification of the most appropriate cannulation site should be undertaken before insertion. If venous access continually proves difficult, placement of a central venous access device should be considered. The following are among the conditions of the cannulation site:
 - a) Large veins in the forearm are recommended for peripheral administration.
 - b) Cannulation should be avoided over joints.
 - c) The inner wrist and the lower extremities should not be used.
 - d) Veins in the antecubital fossa or on the dorsum of the hand, particularly for vesicant drugs, are not recommended.
 - e) Avoid cannulation where lymphoedema is present.
 - f) Cannulation on the side of a mastectomy is still a matter of discussion.
- 'Cannula'. Preventive measures related to the type of cannula include:
 - a) Winged steel infusion devices ('butterfly' needles) must not be used for infusion of vesicant drugs as the needle can be easily displaced or puncture the venous wall.
 - b) Flexible cannulae should be used.
 - c) For infusion of vesicant drugs of longer duration (e.g. 12–24 hours) the central venous access is highly recommended.
- 'Procedures':
 - a) After cannulation, check for blood flow. Then, flush with 10-ml normal saline and check for signs of extravasation.
 - b) Flushing with 10–20 ml of saline solution between different drug infusions is recommended.
 - c) A blood return (flashback) should always be obtained before drugs are administered and checked regularly throughout the bolus infusion.
 - d) Continue monitoring of the cannula insertion site and check regularly for the appearance of symptoms such as swelling, pain or redness sluggish infusion rate. This is highly recommended during infusion of all drugs.
 - e) Bolus dosages of vesicant drugs may be administered concurrently with a fast-running infusion of compatible i.v. fluid.

diagnosis

Patients must be informed to report any changes in sensation, signs or symptoms during the i.v. administration of any chemotherapy drug and to alert the healthcare professional to early signs of extravasation. Particular information must be given when a vesicant drug is administered.

Extravasation must be suspected if any of the specific signs or symptoms are present. Initially, among the most common symptoms are feelings of tingling, burning, discomfort/pain or swelling, and redness at the injection site. Later symptoms may include blistering, necrosis and ulceration.

Signs that frequently raise suspicion of an eventual extravasation are the absence of blood return, resistance on the plunger of the syringe during delivery of a bolus drug, or an interruption to the free flow of an infusion.

If an extravasation is suspected, the cannula should never be removed immediately and general and specific measures should be started.

Table 4. Chemotherapy drugs possibly causing local reactions

Local skin reactions	Chemical phlebitis
Asparaginase	Amsacrin
Cisplatin	Carmustin
Daunorubicin	Cisplatin
Doxorubicin	Dacarbazine
Epirubicin	Epirubicin
Fludarabine	5-Fluorouracil (as continual infusion in combination with cisplatin)
Mechlorethamin	Gemcitabine
Melphalan	Mechlorethamine
	Vinorelbine

differential diagnosis

A differential diagnosis assessment should be carried out if an extravasation is suspected. Some chemotherapy drugs, even if correctly administered, can cause a local reaction which resembles an extravasation. This should not be confused with a true extravasation. Signs and symptoms of local nonextravasation reactions include erythema around the cannula site and along the accessed vein ('flare'), urticaria and local itching. Drugs that may cause these reactions are shown in Table 4.

Another potential differential diagnosis is chemical phlebitis. This vein inflammation, frequently followed by a thrombosis or sclerosis of the veins, may cause a burning sensation at the cannula site and cramping along the vein proximal to the cannula site. This chemical phlebitis can be caused by several drugs (see Table 4).

management of extravasations

No randomized trials on the treatment of extravasation have been carried out until now for ethical reasons as well as certain difficulties in including an adequate number of patients in such a trial. However, many extravasations may cause very little damage if left untreated and only a comparative study with a control group receiving the standard local care would allow clinicians to clearly define the efficacy of an antidote.

Many of the reported management policies for extravasations are based on non-biopsy confirmed data and in many cases, simultaneous treatment with antibiotics was initiated. It should be also considered that many of the recommendations date back to a drug's original registration, which can be several decades ago when requirements for approval were less strict.

general measures

Regardless of the chemotherapy drug, early initiation of treatment is considered mandatory. In this context, patient education is crucial for a prompt identification of the extravasation. The initiation of general unspecific measures as soon as an extravasation is diagnosed is highly recommended [10] (See Figure 1) [V, A]. For that purpose, it is highly recommended that every department that administers

chemotherapy has trained persons who know what to do in case of extravasation. An extravasation kit containing instructions, materials and medication to handle any incidence should be always available. An early multidisciplinary evaluation by nurses, medical oncologists and surgeons is recommended.

specific measures (antidotes)

Various suggestions have been published with possible topical or injected pharmacologic methods for certain vesicant chemotherapy drugs. One should be aware that many are considered ineffective or further damage the extravasated area.

It should be noted that many of these substances are not available or at best have limited access for use in many European countries [5, 7, 11].

local injection or topical corticosteroids

A single-arm clinical study in 53 patients with extravasations due to different drugs (21 with old lesions and 32 with recent extravasations) showed that multiple subcutaneous injections of hydrocortisone followed with topical betamethasone prevented tissue necrosis or sloughing necessitating surgical treatment. In fact, none of the patients was submitted to surgical debridement and all lesions were resolved. Healing time depended on the extent of extravasation and the type of drug [12]. However, in a retrospective series of 175 cases of extravasation, up to 46% patients receiving intralesion corticoids needed surgical debridement versus only 13% of those without corticoids, suggesting a deleterious effect of these agents [5, 11]. In this context, subcutaneous corticoids are not recommended [V, C].

sodium thiosulfate

Mechlorethamine is a DNA-binding vesicant that produces severe and prolonged skin ulceration after extravasation. In several animal experiments, sodium thiosulfate was not able to prevent mechlorethamine skin toxicity when given i.v. immediately before or after extravasation. However, when given immediately after extravasation by intradermal injection, it had a protective effect [13]. Therefore, in humans the recommendation in case of mechlorethamine extravasation is an immediate subcutaneous administration of 2 ml of 1/6 molar solution of sodium thiosulfate which can be obtained by mixing 4 ml of 10% sodium thiosulfate and 6 ml of sterile water for injection; 2 ml of the solution is injected for each milligram of mechlorethamine suspected to have extravasated [V, C].

DMSO

Dimethyl sulfoxide (DMSO) is a common solvent that penetrates tissue when applied topically. This compound has free-radical scavenging properties and has the capacity to speed up the removal of extravasated drugs from tissues.

Despite the initial discouraging results of DMSO in animal models [14], in the 1980s, a prospective pilot trial in 20 patients showed clinical benefit in the management of anthracycline extravasation [15]. Topical DMSO was applied immediately after extravasation covering twice the area affected. This treatment was repeated twice daily for 14 days. No

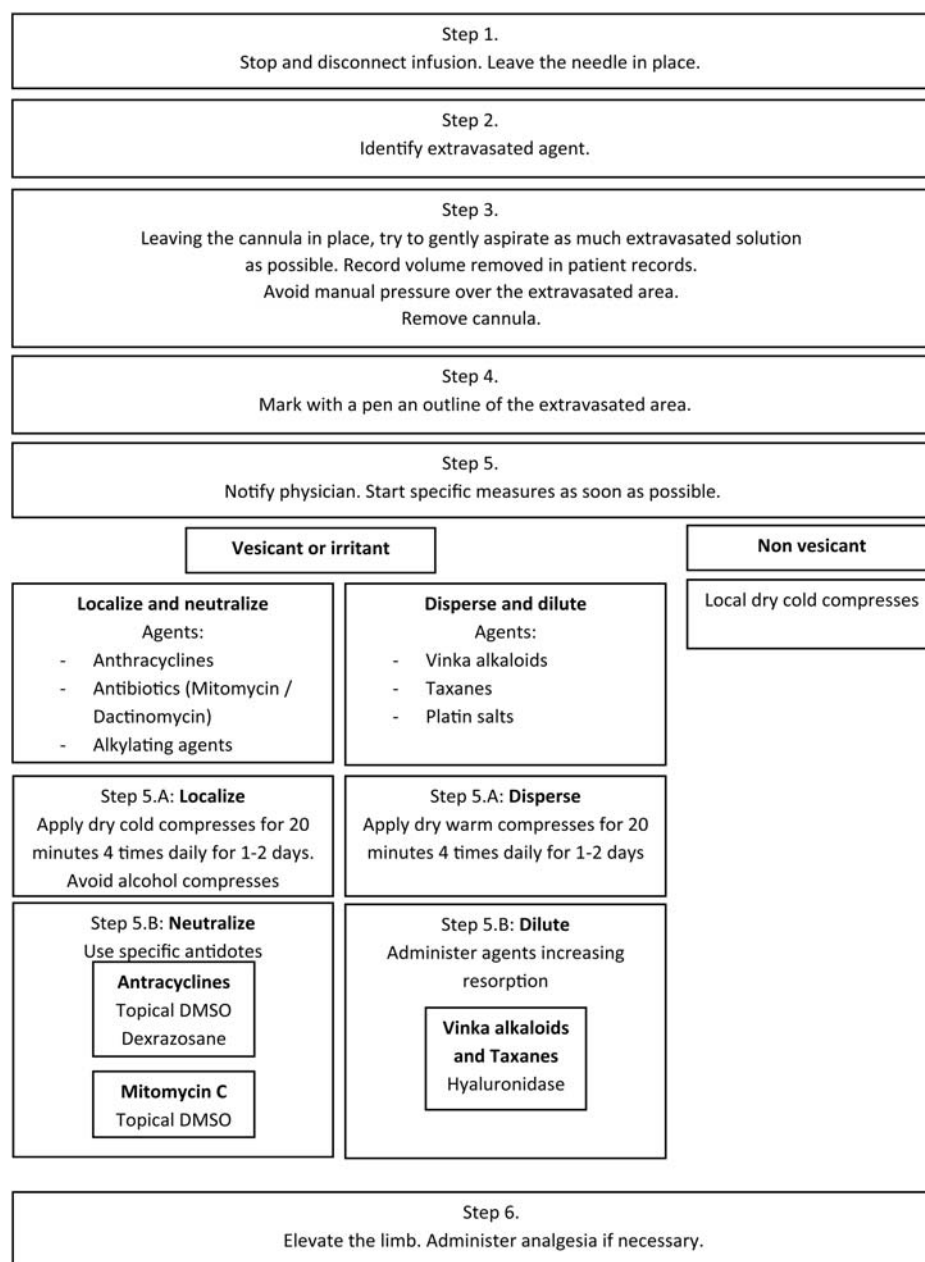


Figure 1 Steps to be taken in case of peripheral line extravasation.

ulceration developed and no surgical intervention was necessary.

In 1995, a series of 144 patients [3] treated with DMSO after inadvertent extravasation secondary to several chemotherapy drugs including doxorubicin ($n = 11$), epirubicin ($n = 46$), mitomycin ($n = 5$), mitoxantrone ($n = 13$), cisplatin ($n = 44$), carboplatin ($n = 6$), ifosfamide ($n = 14$) and fluorouracil ($n = 5$) was reported. In these patients, DMSO 99% was topically applied at four drops per 10 cm² of skin surface twice over an area that was affected and left to air dry without dressing. The application was repeated every 8 h for 1 week. Administration of DMSO was performed in the first 10 min after extravasation in 84% of the patients. Only 1 patient presented ulceration

after epirubicin extravasation. Topical DMSO is a treatment option in extravasations occurred during anthracyclines, mitomycin C or platin salts infusion [III, B]. It should be noted that DMSO 99% can cause local erythema which could affect the correct evaluation of the tissue damage. Some countries have only DMSO at a concentration of 50% available.

dexrazoxane

Dexrazoxane has been used successfully to reduce cardiac toxicity in patients receiving anthracycline-based chemotherapy for cancer (predominantly women with advanced breast cancer) [16]. The drug is thought to reduce the cardiotoxic effects of anthracyclines by binding to free and bound iron, thereby

reducing the formation of anthracycline-iron complexes and the subsequent generation of reactive oxygen species which are toxic to surrounding cardiac tissue [17].

Langer et al. [18] demonstrated that systemic dexrazoxane prevented anthracycline wound formation when administered 3 h after extravasation in a mouse model.

One single systemic dose of dexrazoxane immediately after s.c. administration of doxorubicin, daunorubicin, or idarubicin reduced the tissue lesions (expressed as area under the curve of wound size times duration) by 96%, 70%, and 87%, respectively. The protective effect of dexrazoxane was dose-dependent and it could be administered until 3 h later without loss of protection.

Systemic treatment with dexrazoxane recently proved to be significantly protective in mice, against extravasation of other anthracyclines such as amrubicin, mitoxantrone and liposomal pegylated doxorubicin [19].

Two prospective single-arm clinical trials demonstrated that i.v. dexrazoxane prevented severe tissue damage following anthracycline extravasation. Among the 54 patients included in the trials only one (1.8%) finally needed surgical tissue debridement. Dexrazoxane was administered i.v. in a 3-day schedule (1000, 1000 and 500 mg/m²) starting no later than 6 h after the extravasation event [20]. Dexrazoxane was well tolerated. Hematologic toxicity, hypertransaminasemia, nausea and local pain at the site of the dexrazoxane infusion were the most frequent toxic effects attributed to dexrazoxane [21]. It should be considered that in patients with creatinine clearance values <40 ml/min dexrazoxane should be reduced to 50%. DMSO should not be applied and topical cooling (i.e. ice packs) should be removed 15 min before and during the administration. Dexrazoxane as an i.v. administration in a large vein in an area away from the extravasation (i.e. the opposite arm) is recommended after anthracycline extravasation [III, B].

hyaluronidase

Hyaluronidase is an enzyme that degrades hyaluronic acid, improving the absorption of extravasated drugs. One study [22] in animal models analyzed the impact on ulcer formation of local infiltration with sodium heparine, hyaluronidase or saline. Infiltration with hyaluronidase decreased the ulcer rate by 50–60% and decreased ulcer size by up to 50%.

In 1994 [23], a study on seven patients with accidental vinca alkaloids extravasation showed no skin necrosis after treatment with local hyaluronidase. These data suggested that hyaluronidase might be efficacious in preventing skin necrosis by extravasation due to vinca alkaloids [V, C] (see Table 4). A dose of 1–6 ml of 150 U/ml solution is injected through the existing i.v. line. The usual dose is 1 ml of hyaluronidase solution for 1 ml of extravasated drug.

surgical management of severe tissue damage

The treatment of unresolved tissue necrosis or pain lasting more than 10 days is surgical debridement. It is considered that only one-third of extravasations progress to ulceration [24]. Thus, surgical procedures are relegated to those severe extravasations or to patients in whom conservative therapy has

not been appropriately initiated. Such a procedure should consist of wide, three-dimensional excision of all involved tissue, temporary coverage with a biologic dressing, and simultaneous harvesting and storage of a split-thickness skin graft. Once the wound is clean, delayed application of the graft is performed (usually at 2–3 days) [5] [IV, B].

Subcutaneous wash-out procedure is a surgical technique that has been tested in 13 patients not treated with antidotes or topical treatment as unique immediate therapy to extravasation. The mean time interval to the subcutaneous wash-out was 345 min and none of the patients developed a tissue breakdown during a 3-month follow-up period [25]. Nevertheless, due to scarce experience, this technique cannot be recommended as routine management in a nonexperienced surgical unit [V, C].

documentation

Each incident of extravasation must be correctly documented and reported. Documentation procedure may differ between treatment centers; however, certain items are mandatory for patient safety and for legal purposes:

- (i) Patient name and number
- (ii) Date and time of extravasation
- (iii) Name of drug extravasated as well as diluant used (if applicable)
- (iv) Signs and symptoms (also reported by patient)
- (v) Description of the i.v. access
- (vi) Extravasation area (also the approximate amount of drug)
- (vii) Management steps with time and date

Photographic documentation can be helpful for the follow-up procedures and decision-making. The patient must be informed about the scope of the problem. If a vesicant drug has extravasated, information about the time involved in the resolution, as well as legal implications must be addressed.

central venous access device extravasation

Extravasation of chemotherapy agents administered through a CVAD is a rare complication. In a recent series of 815 patients, this complication occurred in only 0.24% [26]. In this situation, the solution may accumulate in the mediastinum, pleura or in a subcutaneous area of the chest or neck. The most frequent symptom of central line extravasation is acute thoracic pain. Diagnosis must be based on clinical presentation and confirmed with imaging techniques, usually a thoracic CT scan [V, A]. Data about management and evolution are based on case reports. The management of this infrequent extravasation should include stopping of the infusion and aspiration through the central venous catheter of as much amount of the solution as possible. If the extravasated agent is an anthracycline, dexrazoxane might be considered as an antidote [V, C].

Although in most reported cases conservative therapy was preferred, surgical procedures with the objective of draining the remaining solution might be considered [V, C]. Antibiotics,

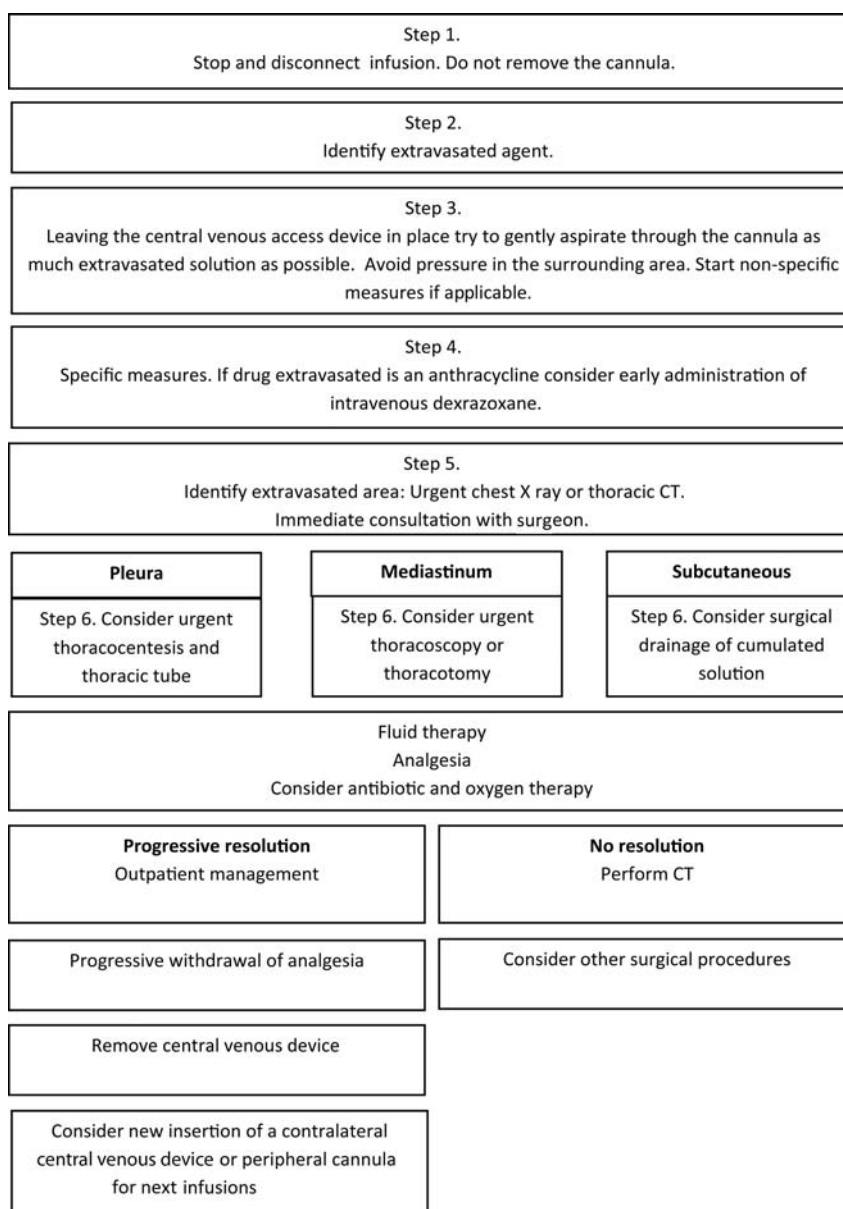


Figure 2 Steps to be taken in case of central venous access device extravasation.

i.v. corticoids, analgesia and other treatments leading to the control of the symptoms derived from the mediastinitis or pleuritis secondary to extravasation can be considered [V, B] (see Figure 2).

follow-up

Data about extravasation follow-up and management follow-up are scarce. In order to initiate the most appropriate follow-up, clinicians should be aware that early vesicant extravasation signs or symptoms can be subtle and not always evident. However, in the following days, initial inflammation increases with more redness, edema and pain. Finally, depending on the vesicant drug, after several days or weeks blisters may appear and inflammation evolve to a necrosis [27]. In this context, it is recommended that the patient should be regularly reviewed,

possibly daily or every 2 days for follow-up during the first week and then weekly until complete resolution of symptoms. If required, referral to a (plastic) surgeon is recommendable. Patients must be informed about the follow-up policy before leaving the treatment area [V, B].

conflict of interest

Dr. Roila has reported: consultancy/honoraria: Merck Sharp & Dohme, Roche; research funding to department: Bristol-Myers Squibb, Merck Sharp & Dohme, GlaxoSmithKline, Sanofi Aventis, AstraZeneca. Ms. Vidall has reported: speakers' bureau support for educational talks on behalf of UKONS (UK Oncology Nursing Society) and staff training in extravasation from SpePharm Ltd and has declared that this manuscript has

Table 5. Recommended suggested specific antidotes to be used after extravasation of some several anticancer agents

Extravasated drug	Suggested antidote	Level of evidence
Anthracyclines	Dexrazoxane i.v. Start as soon as possible (no later than 6 h) at a 1000 mg/m ² dose on day 1 and day 2 and at 500 mg/m ² on day 3.	III-B
Anthracyclines	Topical DMSO (99%). Start as soon as possible (preferably in the first 10 min). It should be applied every 8 h for 7 days.	IV-B
Mytomicin C	Topical DMSO (99%). Start as soon as possible (preferably in the first 10 min). It should be applied every 8 h for 7 days.	IV-B
Mechlorethamine	Sodium thiosulfate 0.17 M in subcutaneous injection. Start immediately. Subcutaneous injection of 2 ml of solution made from 4 ml sodium thiosulfate + 6 ml sterile water.	V-C
Vinka alkaloids	Hyaluronidase in subcutaneous injection. Administer 150-900 IU around the area of extravasation.	V-C
Taxanes	Hyaluronidase in subcutaneous injection. Administer 150-900 IU around the area of extravasation.	V-C

been produced independently of any funding from industry or commercial organizations.

Other authors have reported no potential conflicts of interest.

references

- Allwood M, Stanley A, Wright P (eds). *The Cytotoxics Handbook*, 4th edn 2002. UK: Radcliffe Medical Press Inc.
- Larson DL. Treatment of tissue extravasation by antitumor agents. *Cancer* 1982; 49: 1796–1799.
- Bertelli G, Gozza A, Forno GB et al. Topical Dimethylsulfoxide for the Prevention of Soft Tissue Injury After Extravasation of Vesicant Cytotoxic Drugs: A Prospective Clinical Study. *J Clin Oncol* 1995; 13: 2851–2855.
- Mader I, Fürst-Weger P, Mader R et al. *Extravasation of Cytotoxic Agents; Compendium for Prevention and Management*, 2nd edition. New York: Springer Verlag 2009.
- Schulmeister L. Extravasation management: clinical update. *Semin Oncol Nurs* 2011; 27(1): 82–90.
- Schulmeister L. Extravasation. In Olver IN (ed), *The MASCC Textbook of Cancer Supportive Care and Survivorship*. Heidelberg: Springer 2011; doi:10.1007/978-1-4419-1225-1_34.
- European Oncology Nursing Society (EONS). *Extravasation Guidelines 2007*. [http://www.cancernurse.eu/documents/EONSClinicalGuidelinesSection6-en.pdf#search="extravasation guideline"](http://www.cancernurse.eu/documents/EONSClinicalGuidelinesSection6-en.pdf#search=) (1 June 2012, date last accessed).
- Langstein HN, Duman H, Seelig D et al. Retrospective study of the management of chemotherapeutic extravasation injury. *Ann Plast Surg* 2002; 49: 369–374.
- WOSCAN Cancer Nursing and Pharmacy Group. *Chemotherapy Extravasation Guideline 2009*. <http://www.beatson.scot.nhs.uk/content/mediaassets/doc/Extravasation%20guidance.pdf> (16 May 2012, date last accessed).
- European Oncology Nursing Society. *Extravasation guidelines*. *Eur J Oncol* 2008; 12: 357–361.
- Langer SW, Sehested M, Jesen PB. Anthracycline extravasation: a comprehensive review of experimental and clinical treatments. *Tumori* 2009; 95: 273–282.
- Tsavaris NB, Karagiaouris P, Tzannou I et al. Conservative approach to the treatment of chemotherapy-induced extravasation. *J Dermatol Surg Oncol* 1990; 16: 519–522.
- Dorr RT, Soble M, Alberts DS. Efficacy of sodium thiosulfate as a local antidote to mechlorethamine skin toxicity in mouse. *Cancer Chemother Pharmacol* 1988; 22: 299–302.
- Dorr RT, Alberts DS. Failure of DMSO and vitamin E to prevent doxorubicin skin ulceration in the mouse. *Cancer Treat. Rep* 1983; 67: 499–501.
- Olver IN, Aisner J, Hament A et al. A prospective study of topical dimethyl sulfoxide for treating anthracycline extravasation. *J Clin Oncol* 1988; 6: 1732–1735.
- Wiseman LR, Spencer CM. Dexrazoxane. A review of its use as a cardioprotective agent in patients receiving anthracycline-based chemotherapy. *Drugs* 1998; 56: 385–403.
- Hensley ML, Schuchter LM, Lindley C et al. ASCO Clinical Guidelines for the use of chemotherapy and radiotherapy protectants. *J Clin Oncol* 1999; 17: 3333–3335.
- Langer SW, Sehested M, Jensen PB. Treatment of anthracycline extravasation with dexrazoxane. *Clin Cancer Res* 2000; 6: 3680–3686.
- Langer SW, Thougard AV, Sehested M et al. Treatment of experimental extravasation of amrubicin, liposomal doxorubicin, and mitoxantrone with dexrazoxane. *Cancer Chemother Pharmacol* 2012; 69: 573–576.
- Mouridsen HT, Langer SW, Buter J et al. Treatment of anthracycline extravasation with Savene (dexrazoxane): results from two prospective clinical multicentre studies. *Ann Oncol* 2007; 18: 546–550.
- Langer SW. Treatment of anthracycline extravasation from centrally inserted venous catheters. *Oncol Rev* 2008; 2: 114–116.
- Disa JJ, Chang RR, Muci SJ et al. Prevention of adriamycin-induced full-thickness skin loss using hyaluronidase infiltration. *Plast Reconstr Surg* 1998; 101: 370–374.
- Bertelli G, Dini D, Forno GB et al. Hyaluronidase as an antidote to extravasation of Vinca alkaloids: clinical results. *J Cancer Res Clin Oncol* 1994; 120: 505–506.
- Tsavaris N, Komitsopoulou P, Karagiaouris P et al. Prevention of tissue necrosis due to accidental extravasation of cytostatic drugs by a conservative approach. *Cancer Chemother Pharmacol* 1992; 30: 330–333.
- Steiert A, Hille U, Burke W et al. Subcutaneous wash-out procedure (SWOP) for the treatment of chemotherapeutic extravasations. *J Plast Reconstruct Aesthet Surg* 2011; 64: 240–247.
- Narducci F, Jean-Laurent M, Boulanger L et al. Totally implantable venous access port systems and risk factors for complications: a one-year prospective study in a cancer centre. *Eur J Surg Oncol* 2011; 37: 913–918.
- Kerker B, Hood A. Chemotherapy-induced cutaneous reactions. *Semin Dermatol* 1989; 8: 173–181.