

**SPECIAL ARTICLE**

# Anal cancer: ESMO Clinical Practice Guidelines for diagnosis, treatment and follow-up<sup>☆</sup>

S. Rao<sup>1</sup>, M. G. Guren<sup>2</sup>, K. Khan<sup>3,4</sup>, G. Brown<sup>5</sup>, A. G. Renehan<sup>6</sup>, S. E. Steigen<sup>7</sup>, E. Deutsch<sup>8</sup>, E. Martinelli<sup>9</sup> & D. Arnold<sup>10</sup>,  
on behalf of the ESMO Guidelines Committee<sup>\*</sup>

<sup>1</sup>GI Unit, Royal Marsden Hospital, London, UK; <sup>2</sup>Department of Oncology, Oslo University Hospital, Oslo, Norway; <sup>3</sup>Department of GI Oncology, University College Hospital, London; <sup>4</sup>UCL Cancer Trials Centre, UCL Cancer Institute, London; <sup>5</sup>Department of Radiology, Royal Marsden NHS Foundation Trust, London; <sup>6</sup>Division of Cancer Sciences, School of Medical Sciences, Faculty of Biology, Medicine and Health, University of Manchester, The Christie NHS Foundation Trust, Manchester, UK; <sup>7</sup>Department of Clinical Pathology, University Hospital of North Norway, Tromsø, Norway; <sup>8</sup>INSERM 1030, Gustave Roussy Cancer Campus, Université Paris-Saclay, Villejuif, France; <sup>9</sup>Department of Precision Medicine, Università degli Studi della Campania Luigi Vanvitelli, Naples, Italy; <sup>10</sup>Department of Hematology, Oncology, Palliative Care Medicine and Rheumatology, Asklepios Hospital Altona, Hamburg, Germany



Available online 24 June 2021

**Key words:** anal cancer, clinical practice guidelines, diagnosis, treatment, follow-up

## INCIDENCE AND EPIDEMIOLOGY

Anal cancer is a rare disease that accounts for <1% and <3% of all new cancer diagnoses and gastrointestinal tumours, respectively. The most common histological subtype is squamous-cell carcinoma of the anus (SCCA) with an annual incidence of 0.5-2.0 in 100 000.<sup>1</sup> However, the incidence of anal cancer in Europe, Australia and the United States is increasing.<sup>1</sup> Globally, there were ~40 000 new cases of anal cancer estimated in 2012, and in the United States, there has been a more than doubling increase in the reported number of new, age-adjusted cases per 100 000 people per year over last 40 years.<sup>1</sup>

Five-year overall survival (OS) has increased from a mean estimate of 64% [95% confidence interval (CI) 58% to 71%] in 1980 to 75% (95% CI 70% to 79%) in 2010 ( $P = 0.046$ ).<sup>2</sup>

## Aetiology

SCCA and its precursor lesion, anal intraepithelial neoplasia (AIN), are mostly attributable to human papillomavirus (HPV) infection, which represents the causative agent in 80%-85% of patients (especially the HPV16 and HPV18 subtypes).<sup>3</sup> Factors increasing the risk of HPV infection and/or modulating a host response and the persistence of this infection appear to affect the epidemiology of this tumour. Anal intercourse and a high lifetime number of sexual partners increase the risk of persistent HPV infection

in men and women, eventually leading to malignancy. Other important risk factors include human immunodeficiency virus (HIV) infection, prior history of anogenital warts, lower genital tract malignancies, immune suppression in transplant recipients, a history of other HPV-related cancers, autoimmune disorders and cigarette smoking.<sup>3-6</sup> Cigarette smoking and HIV infection may also be important in the modulation/persistence of HPV infection and, hence, outcomes from treatment.

## DIAGNOSIS AND PATHOLOGY

### Diagnosis

SCCA often presents with bleeding but diagnosis may be delayed because bleeding is attributed to haemorrhoids. SCCA may also present with any combination of a mass, non-healing ulcer, pain, bleeding, itching, discharge, faecal incontinence and fistulae. Digital anorectal examination is an essential low-cost clinical tool for detection of lesions in the anal area. The diagnosis of anal cancer is made by biopsy-proven histology. The diagnostic algorithm for anal cancer is shown in [Figure 1](#) and the diagnostic work-up for SCCA is shown in [Table 1](#).

### Pathology

**Squamous-cell carcinoma histology.** Histological confirmation is mandatory as histopathological entities other than squamous-cell carcinomas (SCCs) are amongst the differentials, including adenocarcinoma, melanoma, gastrointestinal stromal tumours, poorly differentiated neuroendocrine tumours and lymphoma.

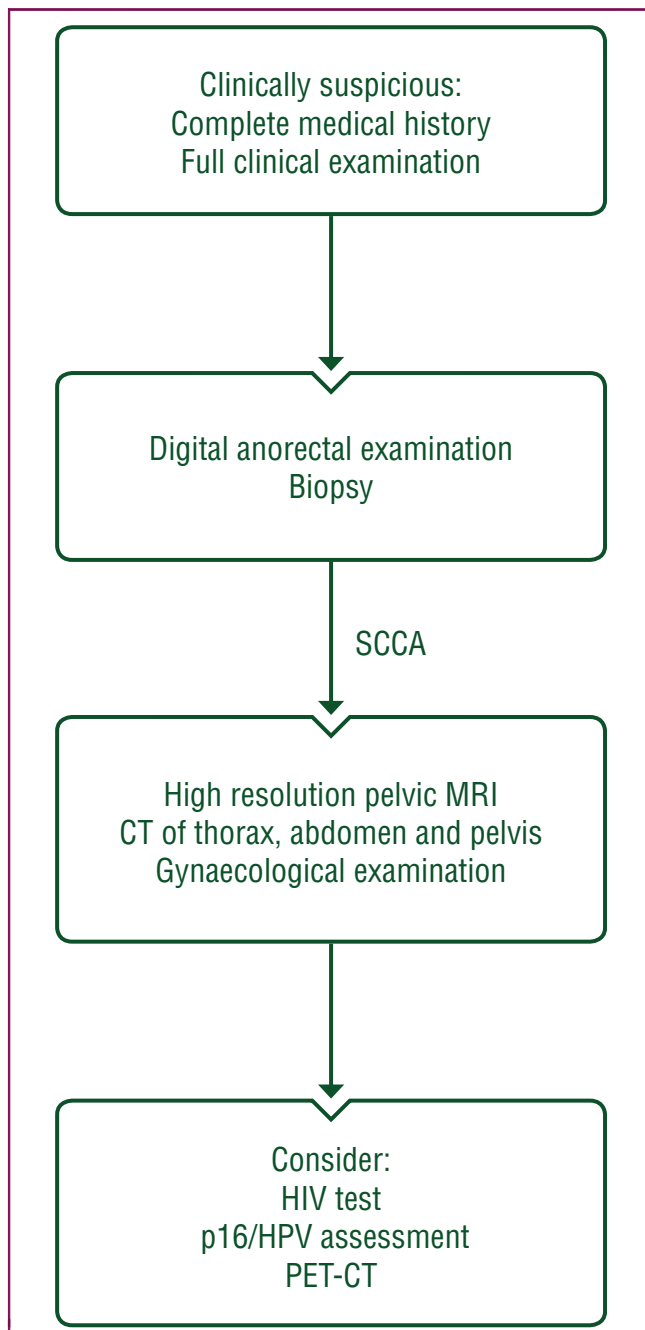
SCCs can harbour various patterns and interpretation is subject to interobserver variability. Histological sub-

<sup>\*</sup>Correspondence to: ESMO Guidelines Committee, ESMO Head Office, Via Geneva 4, CH-6900 Lugano, Switzerland.

E-mail: [clinicalguidelines@esmo.org](mailto:clinicalguidelines@esmo.org) (ESMO Guidelines Committee).

<sup>☆</sup>Note: Approved by the ESMO Guidelines Committee: June 2021.

0923-7534/© 2021 European Society for Medical Oncology. Published by Elsevier Ltd. All rights reserved.



**Figure 1. Diagnostic algorithm for anal cancer.**

CT, computed tomography; HIV, human immunodeficiency virus; HPV, human papillomavirus; MRI, magnetic resonance imaging; PET, positron emission tomography; SCCA, squamous-cell carcinoma of the anus.

classifications of basaloid, transitional, spheroidal and cloacogenic cell cancers have no impact on management, and the recent World Health Organization classification system of anal carcinoma includes all subtypes under the same heading of SCC.<sup>7</sup>

Anal verrucous carcinomas (VCs) are similar to VCs of other sites, and newer studies imply that these lesions are a separate entity not to be included with giant condylomas, also named Buschke—Löwenstein tumours.<sup>8</sup> VC seems to be unrelated to HPV infections while low-risk HPV genotypes are found in giant condylomas. VCs are regarded as low-grade carcinomas while giant condylomas can be

**Table 1. Diagnostic work-up of SCCA**

Mandatory	Recommended	Optional
Biopsy	HIV test	Endo-anal ultrasound
DRE	PET-CT	Ultrasound-guided FNA of inguinal nodes
Complete medical history	P16/HPV assessment	Examination under anaesthesia
Full clinical examination		
High-resolution pelvic MRI		
CT of thorax, abdomen and pelvis		
Anoscopy/proctoscopy		
Gynaecological examination		

CT, computed tomography; DRE, digital rectal examination; FNA, fine needle aspiration; HIV, human immunodeficiency virus; HPV, human papillomavirus; MRI, magnetic resonance imaging; PET, positron emission tomography; SCCA, squamous-cell carcinoma of the anus.

regarded as benign tumours. Histologically, it can be difficult to make a distinction between the two entities but features such as koilocytosis favour condyloma. Occasionally, SCCs arise within giant condylomas.

**AIN.** Anal cancer may arise from a precursor dysplastic lesion, also known as squamous AIN. The American Joint Committee on Cancer recommends dividing these lesions into ‘low-grade’ and ‘high-grade’ squamous intraepithelial lesions (LSILs and HSILs, respectively) with AIN stage I corresponding to LSIL and AIN stages II-III corresponding to HSIL.<sup>9</sup>

The prevalence of AIN in the general population is low, but high-risk sexual behaviour is associated with greater rates of AIN. Further details are described in [Section 1 of the Supplementary Material](https://doi.org/10.1016/j.annonc.2021.06.015), available at <https://doi.org/10.1016/j.annonc.2021.06.015>.

**Anatomy and lymphatic drainage.** The anal canal extends from the anorectal junction to the anal margin (see [Supplementary Figure S1](https://doi.org/10.1016/j.annonc.2021.06.015), available at <https://doi.org/10.1016/j.annonc.2021.06.015>). Useful landmarks are the puborectal sling and the anal verge which roughly coincide with the inter-sphincteric groove. The columnar, or cylindrical epithelium of the rectum, extends to ~1 cm above the dentate line where the anal transitional zone begins. Below the dentate line, the epithelium is all squamous.

Outside the anal verge lies the anal margin. The anal margin is the pigmented skin immediately surrounding the anal orifice, extending laterally to a radius of ~5 cm. Cancer in the anal margin is regarded as anal cancer, while cancer outside 5 cm from the anus is classified as skin cancer (as shown in [Supplementary Tables S1 and S2](https://doi.org/10.1016/j.annonc.2021.06.015), available at <https://doi.org/10.1016/j.annonc.2021.06.015>). Proximally, lymphatic drainage is to perirectal and paravertebral lymph nodes. Immediately above the dentate line, drainage is to internal pudendal nodes and to the internal iliac system. Infra-dentate and perianal skin drains to the inguinal, femoral and external iliac nodes.

**Screening and prevention.** The existence of an identified viral aetiological agent, biological similarities to cervical

cancer and the ability to detect pre-neoplastic lesions may allow the development of screening and prevention programmes. Vaccination against oncogenic HPV is now being recommended for the prevention of cervical cancer, and this may also be of importance for SCCA as infection with HPV is detected in over 90% of invasive anal cancers.<sup>10-12</sup> HPV vaccination programmes are expected to result in lower incidence rates of SCCA.

There are, however, many unanswered questions, including anal HPV natural history, with unknown factors determining rates of progression and regression of the presumed anal cancer precursor, HSIL. Moreover, performance of anal cytology is debatable and outcomes vary based on training and skills of the operator. Psychological and quality-of-life (QoL) aspects of a screening programme should also be considered. A prospective cohort study exploring the epidemiology of anal HPV infection and related abnormalities in a cohort of gay, bisexual and other men who have sex with men (GBMSM) over 35 years of age showed that patient perception of abnormal results may cause poor health-related QoL 2 weeks after screening.<sup>13</sup>

In summary, screening programmes using anal cytology and high-resolution anoscopy have been proposed for high-risk populations (GBMSM and HIV-negative women with a history of anal intercourse or other HPV-related anogenital malignancies) based on achievements obtained in cervical cytology screening.<sup>14,15</sup> However, no randomised controlled study has yet demonstrated a preventive effect of screening in these high-risk populations and thus it cannot be routinely advocated at present.

### Recommendations

- Digital anorectal examination is an essential clinical tool for detection of lesions in the anal area [I, A].
- Biopsy is mandatory to confirm SCCA [I, A].
- All suspicious anal lesions should be excised or biopsied. Targeted biopsy of anal lesions suspicious for AIN is mandatory in high-risk groups to exclude invasive disease [I, B].
- Female patients with AIN should be screened for synchronous cervical intraepithelial neoplasia, vulvar intraepithelial neoplasia and vaginal intraepithelial neoplasia [I, A].
- Consider HIV testing in patients with recurrent or multifocal AIN [V, A].

## STAGING AND RISK ASSESSMENT

### Clinical assessment

A comprehensive history is required to elicit symptoms, other relevant medical conditions, current medications and predisposing factors, which should all be documented. Examination should include digital rectal examination (DRE) to evaluate the anal lesion and any perirectal nodal involvement and, in women (particularly with low anteriorly placed tumours), a vaginal examination to determine the site and size of the primary tumour, vaginal/vaginal septal

involvement, mucosal involvement and exophytic or ulcerative tumour or the presence of a fistula. The presence of a large mass with near obstructing symptoms or a tumour with associated faecal incontinence may require a defunctioning stoma. In women, vaginal involvement may require a prophylactic stoma because of the risk of an anorectal–vaginal fistula. However, since most initial colostomies are not reversed, this decision should be weighed carefully. Palpation of the inguinal nodes is important, particularly superficial inguinal nodes, medial and close to the pubis. Fine needle aspiration (FNA) or biopsy of the suspicious nodes may be considered.

Colonoscopy is not required to assess pathology in the proximal bowel because synchronous colonic lesions are not reported for SCCA. HIV testing should be considered in patients with unknown HIV status (see Figure 1).

### Local staging of primary SCCA

Clinical assessment of the diameter of the tumour has been the modality upon which the TNM (tumour–node–metastasis) classification of SCCA is based (Supplementary Tables S1 and S2, available at <https://doi.org/10.1016/j.annonc.2021.06.015>).<sup>16</sup>

A more detailed assessment of the local tumour and its precise anatomic extent using high-resolution T2-weighted magnetic resonance imaging (MRI) scanning techniques enables optimal assessment [III, A].<sup>17-20</sup>

The tumour needs to be identified in relation to clinical and anatomical landmarks for the purposes of radiotherapy (RT) planning. On MRI, the tumour is shown as a relatively high signal intensity compared with the low signal intensity of the muscle layers that form the internal and external sphincter in the anal canal and the muscularis propria of the rectal wall.<sup>17,21</sup> Conventionally, the radiology report should state the relationship of the lower borders of the tumour to the anal margin, the extent with quadrant involvement of the anal canal or rectum, the craniocaudal length of the tumour and its depth of invasion. Any evidence of adjacent T4 organ infiltration such as vagina, prostate, urethra or bladder wall should also be recorded.<sup>22</sup> In addition, it may be helpful to note the relationship of the tumour/nodes to the sacral segment levels, which would also assist in RT planning [III, B].

The MRI scanning technique uses the same sequences and parameters that have been validated for rectal cancer staging, making use of the anatomic and tumour depiction afforded by high-resolution T2-weighted sequences [III, A].<sup>22,23</sup>

Scans should also cover both inguinal regions, the pelvic sidewall compartments and the top of the mesorectum to the level of L5 so that the primary tumour, as well as draining nodal disease sites, can be imaged. In addition, the lower border of scans should cover the cutaneous anal margin to enable assessment of the anal margin tumours.

Lymph node assessment is notoriously difficult to predict using imaging modalities, and validation of nodal assessment criteria has not been possible due to the paucity of surgical specimens for histopathology correlation. Enlarged inguinal nodes are frequently reactive, and nodes,

whether benign or malignant, will reduce in size following pelvic RT. In general, nodes are more likely to be malignant if they exhibit mixed signal intensity; they are also likely to be malignant if breach of the lymph node capsule by tumour signal intensity is observed. These features are best assessed using high-resolution T2-weighted MRI [III, A].<sup>17</sup>

Primary tumour assessment has now been superseded by MRI; however, contrast-enhanced computed tomography (CT) scanning of the thorax, abdomen and pelvis is a requirement in all patients to assess potential metastatic disease sites at diagnosis and follow-up [III, A].

Reports have shown that positron emission tomography (PET)-CT with [<sup>18</sup>F]2-fluoro-2-deoxy-D-glucose (FDG-PET-CT) is able to characterise inguinal lymph nodes, with two studies providing sufficient data to allow analysis of diagnostic information for PET-CT. A meta-analysis published in 2017 concluded that PET-CT seemed to add value to conventional imaging in the initial staging of patients with T2-4 disease but further high-quality research was required to validate this, mainly because the conventional imaging comparators were highly heterogeneous in the studies analysed. However, there was insufficient evidence to recommend the routine use of PET-CT in the assessment of treatment response or follow-up [III, C].<sup>24</sup>

PET-CT can be used to help confirm suspicious features seen on MRI, particularly if such information will alter the RT plan, for example, in characterising smooth-bordered homogeneous signal intensity enlarged nodes that do not fulfil criteria for malignancy on MRI. Because of the potential additional morbidity from irradiation of the inguinal regions and a high prevalence of enlarged and reactive inguinal lymphadenopathy, further characterisation of enlarged inguinal nodes by ultrasound (US)-guided FNA is helpful when confirmatory features of malignancy are not evident on either MRI or PET-CT scanning [V, C].

Occasionally, an early anal cancer has been inadvertently totally excised before histological confirmation and there is no visible anal tumour on MRI or PET-CT. These are staged as Tx tumours. Reviews of the pathological specimen and of the operative notes are imperative. Commonly these resections are R1 and patients should be considered for chemoradiotherapy (CRT).

### Risk assessment

The presence of HPV infection measured directly or by overexpression of the surrogate marker p16 has a significant effect on patient outcomes. Individuals with HPV-negative tumours are less likely to respond to CRT than those with HPV-positive tumours.<sup>25-27</sup> A meta-analysis has shown that patients with HPV-positive/p16-positive tumours have improved disease-free survival (DFS)/disease-specific survival/relapse-free survival (RFS), progression-free survival (PFS) and OS compared with patients with either HPV-negative/p16-positive or HPV-positive/p16-negative tumours.<sup>28</sup>

The European Organisation for Research and Treatment of Cancer (EORTC) 22861 study demonstrated that skin ulceration, nodal involvement and male sex were independent factors associated with locoregional failure (LRF) and adverse OS.<sup>29</sup> The Radiation Therapy Oncology Group (RTOG) 9811 analysis supported some of the factors previously reported in EORTC 22861 (clinically involved nodes and male sex) and also established tumour diameter of >5 cm as an independent variable predicting DFS and OS.<sup>30</sup>

HIV testing is recommended in any patient with a lifestyle that puts them at risk of contracting HIV infection. Recent evidence suggests that, compared with HIV-negative patients, HIV-positive patients treated with highly active antiretroviral therapy may have similar treatment outcomes.<sup>31</sup> When treating HIV-positive patients with anal cancer, coordinated follow-up with a HIV specialist should be encouraged. Histologically, a high tumour-infiltrating lymphocyte (TIL) count has been found to be significantly associated with RFS in p16-positive tumours.<sup>32</sup> The biological understanding of HPV-positive and -negative tumours is increasing and may be of importance for the design of future clinical trials.<sup>33</sup>

### Recommendations

- All patients with anal tumours should be referred and discussed in a multidisciplinary team (MDT) meeting with a pre-specified interest in anal cancer [V, C].
- Clinical examination including DRE (and vaginal examination in women) and palpation of the inguinal lymph nodes should be carried out for assessment of tumour extent [V, B].
- High-resolution T2-weighted MRI is needed for optimal assessment of primary tumour and lymph nodes [III, A].
- MRI may also be helpful to note the relationship of tumour/nodes to the sacral segment levels, which would also assist in RT planning [III, B].
- Lymph nodes can be difficult to interpret on MRI. Generally, they are more likely to be malignant if they exhibit mixed signal intensity and if breach of the lymph node capsule by tumour signal intensity is observed on high-resolution T2-weighted MRI [III, A].
- Contrast-enhanced CT scanning of the thorax, abdomen and pelvis is a requirement for all patients to assess potential metastatic disease sites at diagnosis and follow-up [III, A].
- Further characterisation of enlarged inguinal nodes by US-guided FNA may be helpful when confirmatory features of malignancy are not evident on either MRI or PET-CT [V, C].
- PET-CT may be considered for staging and assist in RT planning [III, C].
- HIV testing may be considered in at-risk patients [III, C]. Assessment of HPV or p16 status may be considered as they have treatment response predictive value [V, C].

## MANAGEMENT OF LOCAL/LOCOREGIONAL DISEASE

### Initial management of local and locoregional disease

The primary aim of treatment is to achieve cure with locoregional control, preservation of anal function and the best possible QoL. Treatment of anal cancer differs dramatically from that of adenocarcinomas of the lower rectum.

Combinations of mitomycin C (MMC) and 5-fluorouracil (5-FU)-based CRT have been established as the standard of care, leading to complete tumour regression in 80%-90% of patients, with LRFs of ~15%; other cytotoxic agents (mainly cisplatin) can be considered, if clinically indicated.<sup>34,35</sup> A multidisciplinary approach is mandatory, involving radiation oncologists, medical oncologists, surgeons, radiologists and pathologists. The role of surgery as a salvage treatment is accepted.

### CRT

Recommendations are based on results of phase II and six randomised phase III trials [EORTC 22861, United Kingdom Co-ordinating Committee on Cancer Research (UKCCCR) Anal Cancer Trial I (ACT I), RTOG 87-04, RTOG 98-11, ACCORD-03 and Cancer Research United Kingdom (CRUK) ACT II].<sup>29,30,36-40</sup> Concomitant 5-FU and MMC with RT is generally recommended [I, A]. Other options may include 5-FU and cisplatin, and in some cases, other chemotherapy (ChT) combinations can be used.

Relatively few patients with stage I disease were included in the CRT trials and so application of overall data to T1 tumours is limited. However, for small tumours (T1), some investigators have used external beam RT alone followed by a small volume boost. In contrast, early investigators<sup>34,41</sup> reported that CRT with the addition of MMC to 5-FU demonstrated excellent local control in small tumours (<4 cm). Sequential phase II studies with CRT have shown the efficacy of relatively low total RT doses (30-50 Gy) in combination with 5-FU and MMC.<sup>42</sup> In general, CRT is recommended, however the optimal RT dose is not known. The ongoing PLATO (Personalising Anal cancer radioTherapy dose, ISRCTN88455282) trial is a single-protocol 'umbrella platform' comprising the ACT3, 4 and 5 trials, where the ACT4 trial is investigating different RT doses for stage I-IIA anal cancer.<sup>43</sup>

Early randomised controlled European studies have demonstrated that synchronous CRT with 5-FU and MMC as the primary modality is superior to RT alone.<sup>29,40</sup> The RTOG phase III study compared 5-FU with 5-FU and MMC, both in combination with RT. This study confirmed the superiority of the combination of MMC and 5-FU.<sup>30</sup> The 6-8 weeks' treatment gap used in early trials has since been abandoned.

The second generation of randomised studies investigated the role of cisplatin to replace MMC in combination with 5-FU and RT.<sup>37-39</sup> In these studies, cisplatin and 5-FU were also used before or after CRT as neoadjuvant or maintenance treatment, respectively. The results of these studies found that cisplatin in combination with infused 5-FU and RT did not improve either complete response rates or DFS compared with MMC. Induction ChT or maintenance ChT did not

improve outcomes.<sup>37-39</sup> RT was given with total doses of 45-60 Gy depending on treatment protocols (including boost) and disease stage. The optimal RT dose for curative CRT is not clear; however, for patients with locally advanced anal cancer, the RT dose should be >50.4 Gy.<sup>38</sup>

Treatment with 5-FU has been usually given as 1000 mg/m<sup>2</sup> on days 1-4 and 29-32 of RT; alternatively, a 5-day infusion at 800 mg/m<sup>2</sup> has been used by some centres, while MMC has been given either as 12 mg/m<sup>2</sup> (maximum dose 20 mg) on day 1,<sup>38</sup> or 10 mg/m<sup>2</sup> (maximum dose 20 mg) on days 1 and 29.<sup>39</sup> In recent years, based on logistical reasons and availability of data from relatively small case series, 5-FU can be replaced with capecitabine 825 mg/m<sup>2</sup> twice daily, 5 days per week for all days of RT [III, B].<sup>44</sup> A proposed treatment algorithm for the management of localised stage I-III anal cancer is shown in [Figure 2](#).

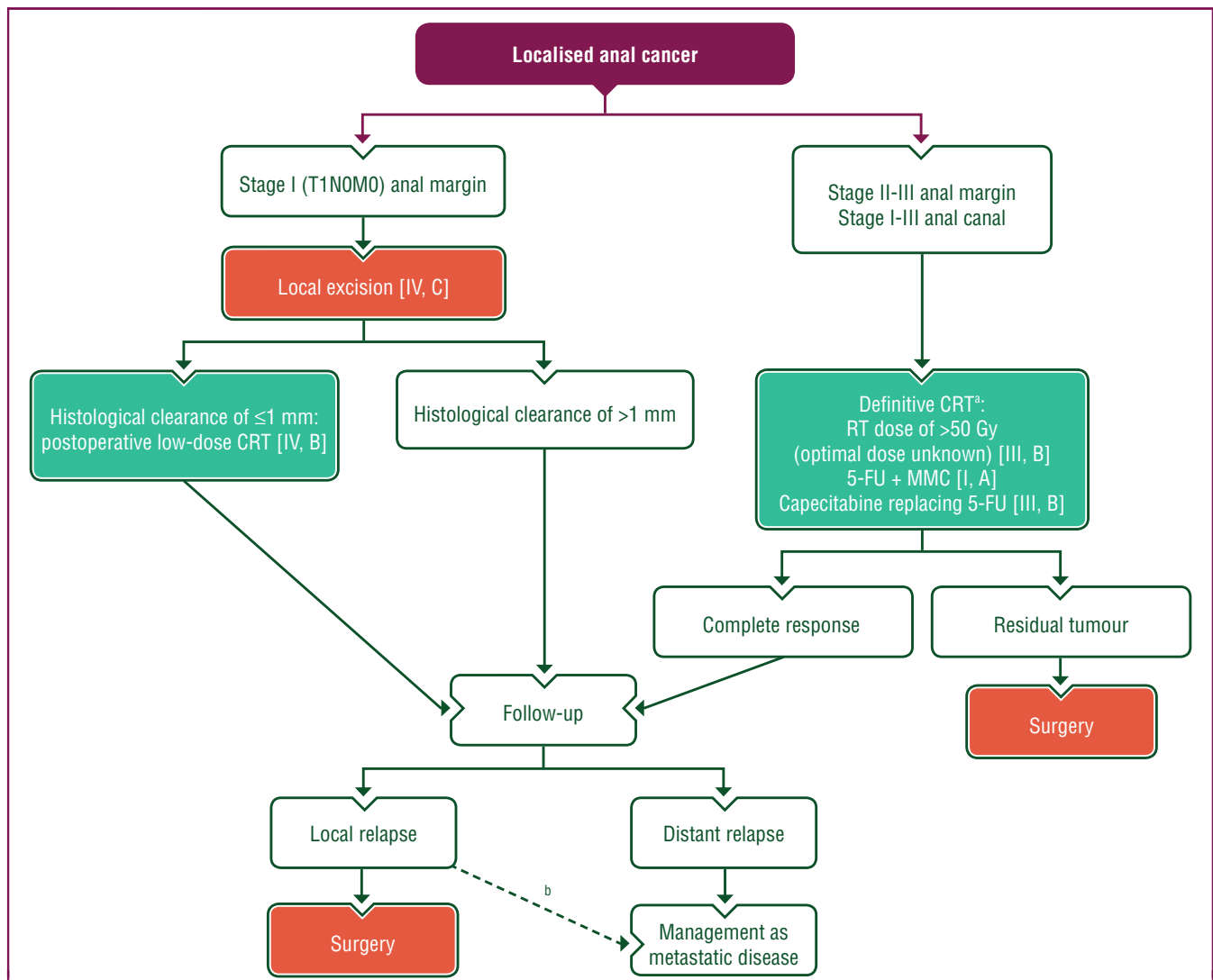
### RT technique and treatment fields

The total doses, including the boost doses used, vary between countries from 50.4 Gy used in the ACT II trial, 55-59 Gy for T3-4 or node-positive disease used in the RTOG 98-11 trial and up to 60 Gy used in a large series from the Nordic countries.<sup>38,39,45</sup> Tumour control probability models suggest that lower doses may be sufficient for small tumours, while higher doses—in the range of 50-55 Gy or higher—may be required for more advanced tumours such as T3-4 or N1.<sup>46,47</sup>

It is not possible to make a definitive recommendation (based on inter-trial comparisons of differing dose fractionations with or without a treatment gap) on the type (external beam or brachytherapy) or dose for a boost after 50 Gy. The optimal RT doses for different target volumes and disease stages are not known and should be determined in randomised clinical trials. In the ongoing integrated PLATO trial, patients with T2N1-3 or T3-4 tumours in the ACT5 trial are randomised to receive total tumour doses of 53.2 Gy, 58.8 Gy or 61.6 Gy in 28 fractions.<sup>43</sup>

Treatment fields should encompass the primary tumour, anal canal, nodal regions and inguinal nodes initially,<sup>48</sup> with field reduction recommended to treat the primary tumour and any sites of likely nodal involvement within the high-dose volume. Alternatively, patients may be treated with simultaneous integrated boost (SIB). Delivery of RT in anal cancer is complex because of the varying size and shape of the target volume and the proximity to dose-sensitive critical structures such as the small bowel, rectum, bladder, femoral heads, perineum and external genitalia. These structures often received high doses of RT with conventional parallel opposed techniques. While earlier randomised trials have mainly relied on two-dimensional-based RT planning, later trials have used conformal [CT-guided or three-dimensional (3D)] RT-based treatments, which allowed oncologists to identify normal as well as target soft tissue structures on axial CT images, and led to improved treatment accuracy and delivery. The most common grade 3-4 acute toxicities were skin, haematological and gastrointestinal.<sup>38,39</sup>

More conformal treatment strategies such as intensity-modulated RT (IMRT) spare at-risk organs, reduce toxicity



**Figure 2. Treatment algorithm for localised anal cancer.**

Purple: general categories or stratification; red: surgery; turquoise: combination of treatments or other systemic treatments; white: other aspects of management. 5-FU, 5-fluorouracil; CRT, chemoradiotherapy; M, metastasis; N, node; MMC, mitomycin C; RT, radiotherapy; T, tumour.

<sup>a</sup> Optimum timepoint to assess clinical tumour response after CRT is 26 weeks [II, B].

<sup>b</sup> In cases where surgery cannot be carried out.

and may allow full or even escalated doses to be achieved within a shorter overall treatment time with limited unplanned treatment interruptions.<sup>49</sup> Hence, IMRT or volumetric modulated arc therapy (VMAT) is currently recommended for the treatment of anal cancer, setting strict RT dose constraints to normal organs [III, B]. Also, IMRT and VMAT allow for treatment with SIB.<sup>50</sup>

Several 'proof-of-principle' studies of IMRT in anal canal carcinoma have reported significant reductions in the RT doses delivered to the bowel, bladder and genitalia/perineal skin. Prospective phase II multicentre studies (including RTOG 0529) have shown that IMRT is deliverable in a multicentre setting,<sup>49,51</sup> with a reduction in toxicity compared with the best arm of the RTOG 9811 trial. Guidance for IMRT with SIB has been developed and is being used in ongoing clinical trials.<sup>52</sup>

Australasian contouring and planning guidelines provide a high-resolution atlas for contouring gross disease and

organs at risk,<sup>48</sup> which complements the earlier RTOG elective anorectal atlas<sup>53</sup> and the RTOG pelvic normal tissue contouring guidelines.<sup>54</sup> The descriptions of the elective target volumes or compartments are useful and reproducible and have been supplemented with recent contouring guidance.<sup>52</sup>

The inguinal nodes should be included in the RT fields in most cases, even in the absence of clearly demonstrable involvement. The incidence of inguinal nodal involvement increases with increasing primary tumour size and is at least 20% in patients with T3 disease. The risk is higher for primary tumours located below the dentate line or near the anal orifice, or in patients with N1 disease.

#### **The role of the surgeon for locoregional anal canal cancer**

The anal cancer surgeon is an important member of the anal cancer MDT.<sup>55</sup> Although 80% of patients with anal

cancer are initially treated by CRT, the anal cancer surgeon should provide input into the management of most patients from the outset. There are four key areas for input as part of initial management.

Approximately 10%-20% of patients with anal cancer will require a pre-treatment colostomy. The two main indications are anorectal pain and faecal incontinence or anticipated faecal incontinence during CRT. In contrast to upper rectal cancers, large bowel obstruction is rare for an anal cancer. Although closure or reversal of colostomy is documented in the literature, it should be considered the exception and only indicated if the anorectum is functionally intact. More commonly, faecal incontinence or anal stenosis persists because of the high RT dose to the anal sphincters, and thus, patients should be advised of the high likelihood that their pretreatment colostomy will be permanent. For the surgical technique, loop colostomy is discouraged because of the high rates of parastomal hernias and prolapses. The technique of choice is an end colostomy, carried out either by open surgery or laparoscopically. CRT can be started 2 weeks after this surgery.

Up to a quarter of patients may have a perianal fistula at the time of anal cancer diagnosis. The fistula may be longstanding as an ano-cryptal fistula unrelated to the malignancy or it may be a malignant fistula. Such fistulae are at high risk for local sepsis during CRT, which may necessitate a treatment gap of >5 days. This is a very unfavourable yet avoidable scenario. The MDT at first diagnosis should specifically document if a fistula is present (clinically or radiologically) and the anal cancer surgeon should insert a seton to secure drainage without delay. The seton might need to remain *in situ* (with 6-monthly changes) for up to 18 months to allow the RT changes to completely settle before definitive fistulotomy. Patients should be fully informed of this potential pathway.

While radical abdomino-perineal excision (APE) has been replaced by CRT as primary treatment for most anal cancers,<sup>56</sup> there are a number of uncommon scenarios where there are relative indications for APE as the primary treatment. These include the following: (i) where there has been previous pelvic RT and curative RT cannot be given; (ii) a histology of anal adenocarcinoma or adenosquamous carcinoma where complete response to RT is less likely than for SCCA; (iii) the setting of SCCA in a transplant patient on immunosuppressants where there may be doubt that the patient will complete CRT uninterrupted; and (iv) an exceptional patient who refuses CRT.

Local excision of early-stage cancers in the anal canal is contraindicated. This is associated with an unacceptably high proportion of margin-positive resections, and if followed by CRT, is associated with considerable morbidity to the anal sphincter.<sup>57</sup> Piecemeal resections (anywhere in the anorectum) are strongly discouraged as it renders assessment of resection margins in the specimen impossible. The only exception is local excision, usually as a biopsy, of very early cancers in the form of superficial invasive SCCA (SISCCA).

A specific mention of VC is warranted. These typically arise in the anal margin, are generally RT-resistant and are

usually treated by local excision. However, VC may be locally infiltrating into the anal sphincters and may necessitate a radical APE. Similarly, giant condylomas mainly arise from the anal margin but may be locally infiltrating necessitating a radical APE.

### Management of anal margin cancer

Up to 5% of all anal cancers are suitable for local excision as definitive treatment. The majority of these are early anal margin cancers (cT1N0M0). The anal margin is defined as the pigmented skin immediately surrounding the anal orifice, extending laterally to a radius of ~5 cm. The aim of this operation is to achieve a histological clearance of >1 mm without damage to the anal sphincter muscle (consensus from the PLATO trialists).<sup>43</sup> This commonly requires a macroscopic surgical clearance of 0.5-1.0 cm. Pre-operative assessment by MRI may be informative for nodal staging, for example, but MRI assessment of external sphincter muscle involvement from a tumour is suboptimal. Direct closure of these wounds has a high risk of wound dehiscence and consideration should be given to a combined procedure with plastic surgery reconstruction.

Approximately 20%, but up to 40% in some series, have a histologically positive margin after local excision. Re-excision has been practiced in this setting, as this is common practice for skin cancers. However, for perianal SCC, this should be discouraged as it is associated with high morbidity, low histological yield and long-term high local recurrence rates. Anal margin SCC is a HPV-related cancer and exquisitely RT-sensitive,<sup>46</sup> and should be considered for low-dose RT with concurrent ChT. PLATO (ACT3) is a non-randomised, phase II, multicentre, open-label trial, primarily in patients with T1N0 anal margin tumours that will assess the overall treatment strategy of local excision with selective low-dose CRT for patients with ≤1 mm margins.<sup>43</sup>

Previous guidelines have recommended that CRT is used, either as the primary treatment or as adjuvant therapy after local excision, irrespective of the resection margin status, where the histology is poorly differentiated.<sup>35</sup> The present authors are unaware of evidence to support or dispute this, and thus considered that no recommendation should be made in relation to tumour differentiation.

A proposed treatment algorithm for the management of localised T1N0M0 anal margin cancer is shown in [Figure 2](#).

### Postoperative CRT

Postoperative CRT should be considered, and discussed in an MDT meeting, for all patients who have had local excision of a cancer in the anal canal, patients who had local excision of an anal margin cancer with a histological margin ≤1 mm, patients who have undergone excision where piecemeal histological assessment and completeness of excision cannot be guaranteed and in those considered at risk of pelvic node involvement [IV, B]. Other indications include rare cases where radical surgery has been carried out as the primary treatment but the resection margin is involved.

Re-excision for a histological positive or close ( $\leq 1$  mm) margin is not recommended.

### Management of elderly patients, toxicity and supportive care

The rationale for treatment recommendations for the elderly and additional considerations regarding toxicity and supportive care during RT as well as brachytherapy are described in [Section 2 of the Supplementary Material](#), available at <https://doi.org/10.1016/j.annonc.2021.06.015>.

### Response evaluation

Anal cancers tend to regress slowly after completion of CRT. DRE has been the mainstay of determining complete response after treatment, defined as the absence of tumour and/or ulceration. Examination may be more informative when carried out under general anaesthesia if pain persists or response is difficult to quantify. Clinical examination of the inguinal regions in addition to radiographic evaluation (with pelvic MRI and CT scans) is also necessary. Oedema, residual fibrosis or scar tissue can be difficult to distinguish from persistent active disease. However, biopsies of persistent, clinically suspicious lesions 8-12 weeks after CRT completion are not routinely recommended. Treatment-related effects may confound the pathological interpretation of post-treatment biopsies.

The majority of tumours that persist/recur typically do so within the first 24 months following completion of CRT.<sup>17</sup> Lack of clinical response at 3 months does not necessarily indicate that surgery is required for non-response since reassessment at 6 months often shows late but clinically significant regression. Using data from the ACT II trial, the optimum timepoint to assess clinical tumour response after CRT was judged to be 26 weeks [II, B].<sup>58</sup>

To date, few FDG-PET-CT studies have assessed treatment response, and the timing of assessment is controversial. If disease progression occurs, salvage surgery is recommended. Residual or 'recurrent' tumour should be confirmed histologically before considering proceeding to radical surgery. The mainstay of salvage is an extra-levator APE.<sup>59</sup>

### Management of local recurrence/regrowth

**Assessment of recurrence/regrowth for salvage surgery.** In patients with histologically confirmed locally recurrent anal cancer, imaging assessment in conjunction with a specialist MDT assessment is important to optimise surgical cure. Involvement of the anal sphincter complex requires exenterative [beyond total mesorectal excision (TME)] surgery, and imaging assessment should include a thorough assessment of the pelvic compartments to enable surgical planning (beyond TME) [III, A].<sup>60-62</sup>

More detailed information on the recommendations for salvage surgery is described in [Section 3 of the Supplementary Material](#), available at <https://doi.org/10.1016/j.annonc.2021.06.015>.

## Recommendations

### Primary treatment

- All patients with anal tumours should be referred and discussed in an MDT meeting with a pre-specified interest in anal cancer [V, C].
- RT with concomitant 5-FU and MMC is recommended as standard of care for patients with localised SCCA [I, A].
- CRT for locally advanced anal cancer should be given with an RT dose of  $>50$  Gy; the optimal dose for different tumour stages is not known [III, B].
- Capecitabine can be possibly used as an alternative to 5-FU in combination with MMC and RT [III, B].
- Neoadjuvant or adjuvant ChT is generally not recommended [I, D].
- Elderly patients who can tolerate treatment should be treated with curative CRT. Patients who cannot tolerate CRT may benefit from RT for local control [V, C].
- The optimal RT dose for primary anal cancer is not known, but doses of at least  $>45-50$  Gy are recommended for T1-2N0 tumours, and doses of 50.4 Gy or higher for T3-4 or N1 tumours [III, B].
- Contouring guidelines are helpful for defining treatment volumes [V, C].
- IMRT, VMAT or 3D conformal RT are the recommended RT techniques, with RT dose constraints to normal tissue [III, B].
- Pre-CRT colostomy should be considered in patients with locally advanced anal cancers with (or anticipated) anorectal pain or faecal incontinence and rectovaginal fistula. Patients should be advised of the likelihood that their colostomy will be permanent [III, C].
- There are uncommon scenarios where radical APE may be considered instead of CRT as the primary treatment, e.g. previous pelvic RT [IV, C].

### Response assessment

- The optimum timepoint to assess tumour response after CRT is 26 weeks [II, B].
- Clinical assessment must be undertaken pre- and post-treatment [II, B].
- A side-by-side comparison of the baseline and post-treatment MRI scans enables an accurate assessment of response [IV, A].
- There is insufficient evidence to recommend the routine use of PET-CT in the assessment of treatment response or follow-up [III, C].

### Toxicity

- Patients should be assessed for skin and haematological toxicity during CRT treatment [III, B].
- Patients should be informed of expected late effects, including changes in anorectal and sexual function, menopause and risk of infertility [IV, C].



### Locally recurrent or residual disease

- Patients with locally residual or recurrent disease after CRT should be considered for salvage surgery [III, B].
- Residual or recurrent tumours may be considered for histological confirmation [II, B].
- For patients with locally recurrent disease, MRI in conjunction with specialist MDT assessment is important to optimise surgical cure [III, A].
- Involvement of the anal sphincter complex requires exenterative surgery, and imaging assessment should include a thorough assessment of the pelvic compartments to enable surgical planning (beyond TME) [III, A].
- The mainstay of salvage surgery is an APE, but more radical exenterative operations can be considered to achieve an R0 resection [III, C].
- APE for relapsed anal cancer is a different operation from that used for rectal cancer. Perineal plastic reconstruction with musculo-cutaneous flaps should be considered in almost all cases [IV, C].
- Patients should be warned that long-term morbidity after salvage surgery is high [IV, C].
- Many organisations in Europe advocate that this specialised multidisciplinary surgery is centralised [IV, B].

### Anal margin cancers

- Early anal margin cancers (cT1N0M0) can be treated definitively by local excision. The aim of this operation is to achieve a histological clearance of >1 mm without damage to the anal sphincter muscle [IV, C].
- CRT is recommended for anal margin cancers (T1N0M0) if the margin is ≤1 mm [III, B].

### MANAGEMENT OF ADVANCED/METASTATIC DISEASE

Approximately 10%-20% of patients suffer distant relapse and ~10% present with *de novo* metastatic disease.<sup>29,36</sup> Twenty percent of patients develop local failures following CRT, and salvage surgery is only feasible for a proportion of such patients.<sup>29,36,63</sup> The common sites of metastatic spread are the para-aortic nodes and the liver, whereas the lungs, bones, peritoneum and skin are involved less frequently. The prognosis of all metastatic patients is poor with a 5-year relative survival rate of 30%. Information on best supportive care is described in [Section 4 of the Supplementary Material](#), available at <https://doi.org/10.1016/j.annonc.2021.06.015>.

### ChT options

Otherwise fit patients with symptomatic metastatic or recurrent disease not amenable to surgery should be considered for ChT. Despite a lack of high-quality prospective evidence, several small case series have shown efficacy in favour of combination therapy with cisplatin and 5-FU.<sup>35,64-66</sup>

Activity has also been reported for carboplatin, doxorubicin, taxanes and irinotecan ± cetuximab, or combinations of these agents.<sup>67-70</sup> These options will be influenced by the disease-free interval and the patient's preferences and performance status. Responses are rarely complete and usually short in duration. Recently, Kim et al. reported encouraging activity in a single-arm phase II trial of triplet ChT with modified docetaxel, cisplatin and 5-FU (DCF).<sup>70</sup>

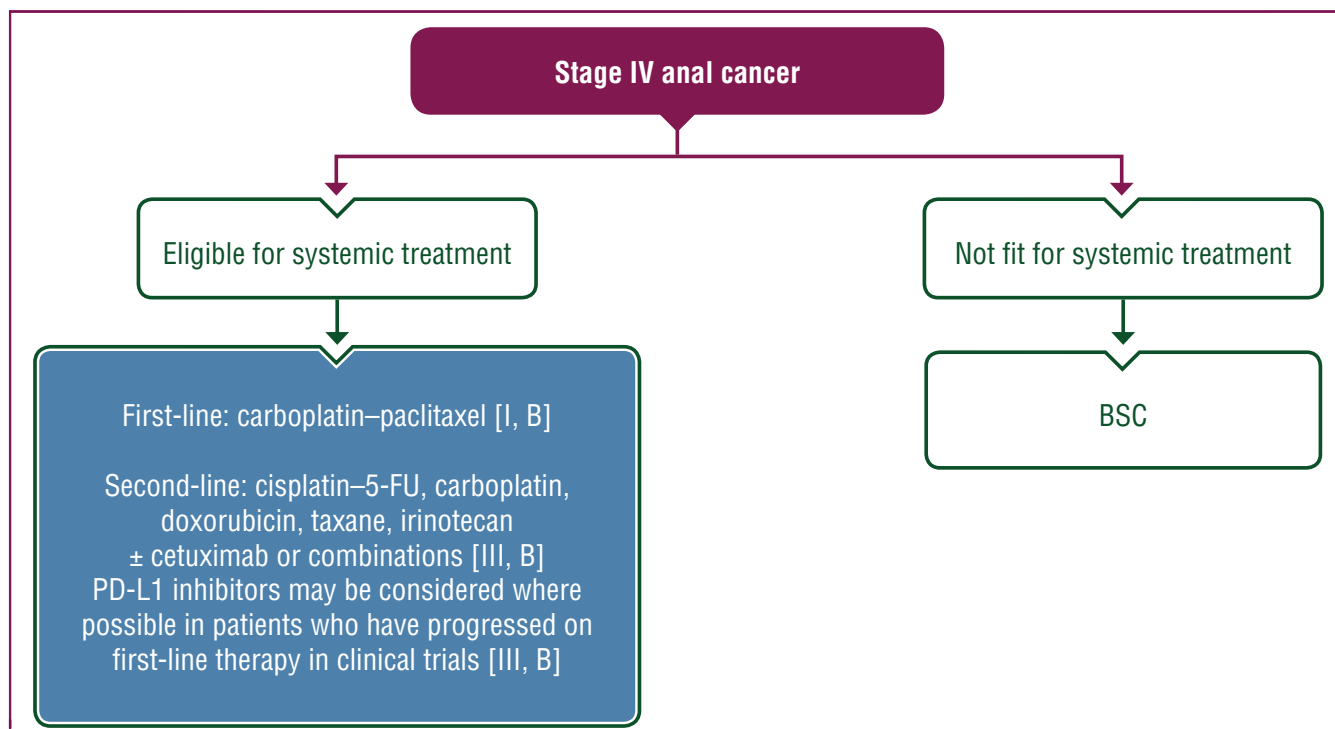
The International Rare Cancers Initiative, which is a consortium of international investigators from the UK, United States, Europe and Australia, reported findings from a multicentre international trial testing the role of carboplatin—paclitaxel versus the common standard of 5-FU—cisplatin. The International Multicentre Study in Advanced Anal Cancer (InterAACT) is the largest and only multicentre randomised controlled phase II study, recruiting 91 patients between 2013 and 2017. Patients were randomly assigned to carboplatin—paclitaxel ( $n = 45$ ) and cisplatin—5-FU ( $n = 46$ ). Median follow-up was 28.6 months. Objective response rate (ORR) was 57% (95% CI 39.4% to 73.7%) for cisplatin—5-FU versus 59% (95% CI 42.1% to 74.4%) for carboplatin—paclitaxel. Median OS was 12.3 months for cisplatin—5-FU (95% CI 9.2-17.7) versus 20 months (95% CI 12.7-not reached) for carboplatin—paclitaxel (hazard ratio 2.00; 95% CI 1.15-3.47,  $P = 0.014$ ).<sup>71</sup> Based on these findings, carboplatin—paclitaxel should be regarded as the standard of care in patients with ChT-naive advanced anal cancer and should be the cytotoxic platform for future phase III trials [I, B].

A proposed treatment algorithm for the management of advanced anal cancer is shown in [Figure 3](#).

### Immunotherapy landscape in anal cancer

Immunotherapy has been deemed an important biological consideration in anal cancer in view of its causal association with HPV infection. Besides the oncogenic properties of HPV viruses, HPV proteins E6 and E7 are known to promote recruitment of TILs, which triggers activation of an anti-cancer immune response. Twenty-four patients with advanced anal cancer and programmed death-ligand 1 (PD-L1)-positive tumours (cut-off ≥1% membrane staining of both neoplastic cells and mononuclear inflammatory cells) were evaluated in the multi-tumour type KEYNOTE-028 study.<sup>72</sup> This study showed encouraging findings with pembrolizumab in a cohort of patients with refractory anal cancer and no other available standard systemic therapy options. The ORR and stable disease (SD) rates were 17% and 42%, respectively. Median duration of response was not reached while median PFS and OS were 3.0 months and 9.3 months, respectively; 1-year survival was 47.6%.

Similar efficacy outcomes were reported in NCI9673, a phase II study investigating the safety and activity of nivolumab in patients who had received ≥1 prior systemic therapy for advanced disease.<sup>73</sup> Of the 37 heavily pre-treated patients with advanced anal cancer, 24% achieved a response (partial response in 19%, complete response in 5%) while SD was achieved in a further 47% of cases. Median PFS and OS were 4.1 months and 11.5 months, respectively. Further



**Figure 3. Treatment algorithm for advanced anal cancer.**

Purple: general categories or stratification; blue: systemic anticancer therapy; white: other aspects of management.

5-FU, 5-fluorouracil; BSC, best supportive care; PD-1, programmed cell death protein 1; PD-L1, programmed death-ligand 1.

testing of programmed cell death protein 1 (PD-1)/PD-L1 inhibitors and other immunotherapy-based approaches is currently underway. Microsatellite instability/mismatch repair testing is not required for the use of PD-1/PD-L1 inhibitors in metastatic anal cancer.

Based on the significant promise shown by such approaches thus far, the authors recommend that clinical trials evaluating the role of immunotherapy in patients with advanced anal cancer should be considered, where possible (Figure 3).

### Recommendations

- Carboplatin in combination with paclitaxel should be considered a new standard of care in patients with ChT-naïve advanced anal cancer [I, B].
- Cisplatin in combination with 5-FU/capecitabine, carboplatin or docetaxel-based combinations are alternatives in patients with ChT-naïve advanced anal cancer [III, B].
- PD-L1 inhibitors may be considered where possible in patients who have progressed on first-line therapy in clinical trials [III, B].

### PERSONALISED MEDICINE

Despite recent developments in our understanding of the molecular biology of anal cancer, there remains considerable heterogeneity in terms of outcomes, particularly for advanced disease stages. One of the major obstacles in establishing clinically relevant biomarkers is the lack of sufficient data from clinical trials owing to small numbers of patients. However, more clinically meaningful information is

emerging from recent studies utilising highly sensitive molecular characterisation techniques and comprehensive genome sequencing panels, and this may influence clinical decision making for patients with anal cancer in the future.<sup>74</sup>

The association between anal cancer and HPV has long been established; the cell cycle regulator p16 is overexpressed in high-risk HPV-related cervical cancers, which may represent a simple surrogate biomarker for identifying SCCs harbouring HPV DNA. Patients with moderate-strong p16 staining may achieve a better response to CRT and have a lower risk of relapse than patients with absent or weak staining. However, more research is needed before a recommendation can be made.<sup>25,27,33</sup> Furthermore, assessment of TILs is thought to add to the prognostic information of HPV status in anal cancer following CRT and provides evidence of the perceived clinical importance of the immune response, although more research is needed.<sup>32</sup> More detailed information on personalised medicine is described in Section 5 of the Supplementary Material, available at <https://doi.org/10.1016/j.annonc.2021.06.015>.

### FOLLOW-UP LONG-TERM IMPLICATIONS AND SURVIVORSHIP

#### Locoregional disease

Follow-up should be considered in all patients within a protocol-driven programme by the anal cancer MDT.

Patients in complete remission should be evaluated every 3-6 months for a period of 2 years, and every 6-12 months

until 5 years, with clinical examination including DRE and palpation of the inguinal lymph nodes [II, B]. Anoscopy or proctoscopy is an additional option but is sometimes poorly tolerated and too painful following CRT. Suspicious lesions should be assessed by MRI and/or PET and be biopsied if possible. Data from the ACT II study suggest that very few (<1%) relapses occur after 3 years so extended imaging surveillance after this time is not recommended [II, C]. Once tumour regression is confirmed at 3 and 6 months, annual CT scans for surveillance at 12, 24 and 36 months are recommended to identify disease relapse or metastatic disease.

### Long-term implications and survivorship

Data on long-term QoL and functional outcomes are relatively sparse but show that disease and treatment can affect anorectal and sexual function. In addition, continence and 'urgency' appear impaired in many patients.<sup>75-77</sup> Acute and late adverse events during IMRT correlate with RT doses to the small bowel and anterior pelvic contents.<sup>78</sup> Pelvic RT usually results in menopause and loss of fertility in women and may also affect male fertility. Information regarding treatment-related side-effects should be provided clearly, particularly on anorectal and sexual functioning.

Several aspects of long-term function and QoL have been identified as among the core outcomes to investigate after treatment for anal cancer.<sup>79</sup> Efforts should therefore be made to document QoL and late effects [V, C]. An anal cancer-specific QoL questionnaire has recently been developed and is currently being validated.<sup>80</sup>

The challenge is to fine-tune the balance between treatment intensity (RT dose and volume) and long-term side-effects given the high cure rate of anal cancer at the locoregional stage.

### Recommendations

- Follow-up should be considered in all patients within a protocol-driven programme by the anal cancer MDT [III, B].
- The primary aim of follow-up is to detect disease which is amenable to salvage therapy; a secondary aim is to manage symptoms related to the cancer and its treatment [III, C].
- Patients in complete remission should be evaluated every 3-6 months for a period of 2 years, and every 6-12 months until 5 years, with clinical examination including DRE and palpation of the inguinal lymph nodes [II, B].
- Very few (<1%) relapses occur after 3 years so extended imaging surveillance after this time is not recommended [II, C].
- Patients with locally advanced anal cancer may benefit from intensive MRI surveillance in the first 12 months [III, C].
- Efforts should be made to document QoL and late effects [V, C].

### METHODOLOGY

This Clinical Practice Guideline was developed in accordance with the ESMO standard operating procedures for Clinical Practice Guidelines development, available at <http://www.esmo.org/Guidelines/ESMO-Guidelines-Methodology>. The relevant literature has been selected by the expert authors. Levels of evidence and grades of recommendation have been applied using the system shown in [Supplementary Table S3](#), available at <https://doi.org/10.1016/j.annonc.2021.06.015>.<sup>81</sup> Statements without grading were considered as justified standard clinical practice by the experts.

### ACKNOWLEDGEMENTS

This Clinical Practice Guideline was reviewed by Arndt Vogel on behalf of the ESMO Guidelines Steering Committee. Manuscript editing support was provided by Angela Corstorphine (Kstorfin Medical Communications Ltd), Louise Green and Catherine Evans (ESMO Guidelines Staff). This support was funded by ESMO.

### FUNDING

No external funding has been received for the preparation of these guidelines. Production costs have been covered by ESMO from central funds.

### DISCLOSURE

DA reports receipt of honoraria for advisory boards, educational activities and/or presentations from Amgen, AstraZeneca, Bayer, Bristol-Myers Squibb, Boston Scientific, Eli Lilly, Merck Serono, Merck Sharp & Dohme, Roche, Sanofi, Servier, Sirtex, Terumo, Art Temp, PriME Oncology and TRM Oncology; travel support from AstraZeneca, Bristol-Myers Squibb, Roche and Sanofi; research funding to institute from AstraZeneca, Incyte, Merck Sharp & Dohme, Roche and Sanofi; and non-remunerated activities (advisory role and/or principal investigator function) for Mologen and Oncolytics. ED reports grants and personal fees from Roche Genentech and Merck Serono and grants from Boehringer Ingelheim, AstraZeneca, Bristol-Myers Squibb and Merck Sharp & Dohme. EM has served as a speaker for Merck Serono, Servier and Amgen, and as an advisor for Pierre-Fabre, Incyte, Bayer, AstraZeneca, Roche, Sanofi and ESMO. MGG has received institutional research funding from Bristol-Myers Squibb, Incyte and Merck Sharp & Dohme. SR reports receipt of honoraria for advisory boards from Bayer, Roche, Servier, Merck Serono and received travel support from Incyte, Bayer and Servier. KK, GB, AGR and SES have declared no conflicts of interest.

### REFERENCES

1. Islami F, Ferlay J, Lortet-Tieulent J, et al. International trends in anal cancer incidence rates. *Int J Epidemiol*. 2017;46(3):924-938.
2. Sekhar H, Zwahlen M, Trelle S, et al. Nodal stage migration and prognosis in anal cancer: a systematic review, meta-regression, and simulation study. *Lancet Oncol*. 2017;18(10):1348-1359.
3. Daling JR, Madeleine MM, Johnson LG, et al. Human papillomavirus, smoking, and sexual practices in the etiology of anal cancer. *Cancer*. 2004;101(2):270-280.

4. de Martel C, Plummer M, Vignat J, et al. Worldwide burden of cancer attributable to HPV by site, country and HPV type. *Int J Cancer*. 2017;141(4):664-670.
5. Bower M, Powles T, Newsom-Davis T, et al. HIV-associated anal cancer: has highly active antiretroviral therapy reduced the incidence or improved the outcome? *J Acquir Immune Defic Syndr*. 2004;37(5):1563-1565.
6. Edgren G, Sparen P. Risk of anogenital cancer after diagnosis of cervical intraepithelial neoplasia: a prospective population-based study. *Lancet Oncol*. 2007;8(4):311-316.
7. Digestive system tumours. In: WHO Classification of Tumours, Editorial Board, ed. *WHO Classification of Tumours*. Vol 1, 5th ed. World Health Organization, 2019.
8. Zidar N, Langner C, Odar K, et al. Anal verrucous carcinoma is not related to infection with human papillomaviruses and should be distinguished from giant condyloma (Buschke-Lowenstein tumour). *Histopathology*. 2017;70(6):938-945.
9. Darragh TM, Colgan TJ, Thomas Cox J, et al. The Lower Anogenital Squamous Terminology Standardization project for HPV-associated lesions: background and consensus recommendations from the College of American Pathologists and the American Society for Colposcopy and Cervical Pathology. *Int J Gynecol Pathol*. 2013;32(1):76-115.
10. Serrano B, de Sanjose S, Tous S, et al. Human papillomavirus genotype attribution for HPVs 6, 11, 16, 18, 31, 33, 45, 52 and 58 in female anogenital lesions. *Eur J Cancer*. 2015;51(13):1732-1741.
11. Baricevic I, He X, Chakrabarty B, et al. High-sensitivity human papilloma virus genotyping reveals near universal positivity in anal squamous cell carcinoma: different implications for vaccine prevention and prognosis. *Eur J Cancer*. 2015;51(6):776-785.
12. De Vuyst H, Clifford GM, Nascimento MC, et al. Prevalence and type distribution of human papillomavirus in carcinoma and intraepithelial neoplasia of the vulva, vagina and anus: a meta-analysis. *Int J Cancer*. 2009;124(7):1626-1636.
13. Cvejic E, Poynten IM, Kelly PJ, et al. Psychological and utility-based quality of life impact of screening test results for anal precancerous lesions in gay and bisexual men: baseline findings from the Study of the Prevention of Anal Cancer. *Sex Transm Infect*. 2020;96(3):177-183.
14. Giuliano AR, Palefsky JM, Goldstone S, et al. Efficacy of quadrivalent HPV vaccine against HPV infection and disease in males. *N Engl J Med*. 2011;364(5):401-411.
15. Kreimer AR, Gonzalez P, Katki HA, et al. Efficacy of a bivalent HPV 16/18 vaccine against anal HPV 16/18 infection among young women: a nested analysis within the Costa Rica Vaccine Trial. *Lancet Oncol*. 2011;12(9):862-870.
16. Brierley JD, Gospodarowicz MK, Wittekind C. *TNM Classification of Malignant Tumours*. 8th ed. Oxford: John Wiley & Sons, Inc; 2016.
17. Koh DM, Dzik-Jurasz A, O'Neill B, et al. Pelvic phased-array MR imaging of anal carcinoma before and after chemoradiation. *Br J Radiol*. 2008;81(962):91-98.
18. Kochhar R, Renehan AG, Mullan D, et al. The assessment of local response using magnetic resonance imaging at 3- and 6-month post chemoradiotherapy in patients with anal cancer. *Eur Radiol*. 2017;27(2):607-617.
19. Gourtsoyianni S, Goh V. MRI of anal cancer: assessing response to definitive chemoradiotherapy. *Abdom Imaging*. 2014;39(1):2-17.
20. Goh V, Gollub FK, Liaw J, et al. Magnetic resonance imaging assessment of squamous cell carcinoma of the anal canal before and after chemoradiation: can MRI predict for eventual clinical outcome? *Int J Radiat Oncol Biol Phys*. 2010;78(3):715-721.
21. Salerno G, Daniels IR, Brown G. Magnetic resonance imaging of the low rectum: defining the radiological anatomy. *Colorectal Dis*. 2006;8(suppl 3):10-13.
22. Brown G, Rimmer M, Williams S. Colon, rectum and anal canal cancer In: Nicholson T, ed. *Recommendations for Cross-Sectional Imaging in Cancer Management*. Vol 2019, 2nd ed. London: The Royal College of Radiologists; 2014. Royal College Recommendations.
23. Brown G, Daniels IR, Richardson C, et al. Techniques and troubleshooting in high spatial resolution thin slice MRI for rectal cancer. *Br J Radiol*. 2005;78(927):245-251.
24. Mahmud A, Poon R, Jonker D. PET imaging in anal canal cancer: a systematic review and meta-analysis. *Br J Radiol*. 2017;90(1080):20170370.
25. Serup-Hansen E, Linnemann D, Skovrider-Ruminski W, et al. Human papillomavirus genotyping and p16 expression as prognostic factors for patients with American Joint Committee on Cancer stages I to III carcinoma of the anal canal. *J Clin Oncol*. 2014;32(17):1812-1817.
26. Gilbert DC, Williams A, Allan K, et al. p16INK4A, p53, EGFR expression and KRAS mutation status in squamous cell cancers of the anus: correlation with outcomes following chemo-radiotherapy. *Radiother Oncol*. 2013;109(1):146-151.
27. Meulendijks D, Tomaso NB, Dewit L, et al. HPV-negative squamous cell carcinoma of the anal canal is unresponsive to standard treatment and frequently carries disruptive mutations in TP53. *Br J Cancer*. 2015;112(8):1358-1366.
28. Sun G, Dong X, Tang X, et al. The prognostic value of HPV combined p16 status in patients with anal squamous cell carcinoma: a meta-analysis. *Oncotarget*. 2018;9(8):8081-8088.
29. Bartelink H, Roelofsens F, Eschwege F, et al. Concomitant radiotherapy and chemotherapy is superior to radiotherapy alone in the treatment of locally advanced anal cancer: results of a phase III randomized trial of the European Organization for Research and Treatment of Cancer Radiotherapy and Gastrointestinal Cooperative Groups. *J Clin Oncol*. 1997;15(5):2040-2049.
30. Flam M, John M, Pajak TF, et al. Role of mitomycin in combination with fluorouracil and radiotherapy, and of salvage chemoradiation in the definitive nonsurgical treatment of epidermoid carcinoma of the anal canal: results of a phase III randomized intergroup study. *J Clin Oncol*. 1996;14(9):2527-2539.
31. Martin D, Balermipas P, Fokas E, et al. Are there HIV-specific differences for anal cancer patients treated with standard chemoradiotherapy in the era of combined antiretroviral therapy? *Clin Oncol (R Coll Radiol)*. 2017;29(4):248-255.
32. Gilbert DC, Serup-Hansen E, Linnemann D, et al. Tumour-infiltrating lymphocyte scores effectively stratify outcomes over and above p16 post chemo-radiotherapy in anal cancer. *Br J Cancer*. 2016;114(2):134-137.
33. Jones CM, Goh V, Sebag-Montefiore D, et al. Biomarkers in anal cancer: from biological understanding to stratified treatment. *Br J Cancer*. 2017;116(2):156-162.
34. Nigro ND, Vaitkevicius VK, Considine B Jr. Combined therapy for cancer of the anal canal: a preliminary report. *Dis Colon Rectum*. 1974;17(3):354-356.
35. Glynne-Jones R, Nilsson PJ, Aschele C, et al. Anal cancer: ESMO-ESSO-ESTRO clinical practice guidelines for diagnosis, treatment and follow-up. *Eur J Surg Oncol*. 2014;40(10):1165-1176.
36. Northover J, Glynne-Jones R, Sebag-Montefiore D, et al. Chemoradiation for the treatment of epidermoid anal cancer: 13-year follow-up of the first randomised UKCCCR Anal Cancer Trial (ACT I). *Br J Cancer*. 2010;102(7):1123-1128.
37. Peiffert D, Tournier-Rangeard L, Gerard JP, et al. Induction chemotherapy and dose intensification of the radiation boost in locally advanced anal canal carcinoma: final analysis of the randomized UNICANCER ACCORD 03 trial. *J Clin Oncol*. 2012;30(16):1941-1948.
38. James RD, Glynne-Jones R, Meadows HM, et al. Mitomycin or cisplatin chemoradiation with or without maintenance chemotherapy for treatment of squamous-cell carcinoma of the anus (ACT II): a randomised, phase 3, open-label, 2 x 2 factorial trial. *Lancet Oncol*. 2013;14(6):516-524.
39. Ajani JA, Winter KA, Gunderson LL, et al. Fluorouracil, mitomycin, and radiotherapy vs fluorouracil, cisplatin, and radiotherapy for carcinoma of the anal canal: a randomized controlled trial. *JAMA*. 2008;299(16):1914-1921.
40. Epidermoid anal cancer: results from the UKCCCR randomised trial of radiotherapy alone versus radiotherapy, 5-fluorouracil, and mitomycin.

- UKCCCR Anal Cancer Trial Working Party. UK Co-ordinating Committee on Cancer Research. *Lancet*. 1996;348(9034):1049-1054.
41. Cummings BJ, Keane TJ, O'Sullivan B, et al. Epidermoid anal cancer: treatment by radiation alone or by radiation and 5-fluorouracil with and without mitomycin C. *Int J Radiat Oncol Biol Phys*. 1991;21(5):1115-1125.
  42. Hatfield P, Cooper R, Sebag-Montefiore D. Involved-field, low-dose chemoradiotherapy for early-stage anal carcinoma. *Int J Radiat Oncol Biol Phys*. 2008;70(2):419-424.
  43. PLATO trial: Personalising Anal cancer radioTherapy dose—incorporating ACT3, ACT4 and ACT5. 2020. ISRCTN registry.
  44. Glynne-Jones R, Meadows H, Wan S, et al. EXTRA—a multicenter phase II study of chemoradiation using a 5 day per week oral regimen of capecitabine and intravenous mitomycin C in anal cancer. *Int J Radiat Oncol Biol Phys*. 2008;72(1):119-126.
  45. Leon O, Guren M, Hagberg O, et al. Anal carcinoma—survival and recurrence in a large cohort of patients treated according to Nordic guidelines. *Radiother Oncol*. 2014;113(3):352-358.
  46. Muirhead R, Partridge M, Hawkins MA. A tumor control probability model for anal squamous cell carcinoma. *Radiother Oncol*. 2015;116(2):192-196.
  47. Johnsson A, Leon O, Gunnlaugsson A, et al. Determinants for local tumour control probability after radiotherapy of anal cancer. *Radiother Oncol*. 2018;128(2):380-386.
  48. Ng M, Leong T, Chander S, et al. Australasian Gastrointestinal Trials Group (AGITG) contouring atlas and planning guidelines for intensity-modulated radiotherapy in anal cancer. *Int J Radiat Oncol Biol Phys*. 2012;83(5):1455-1462.
  49. Kachnic LA, Tsai HK, Coen JJ, et al. Dose-painted intensity-modulated radiation therapy for anal cancer: a multi-institutional report of acute toxicity and response to therapy. *Int J Radiat Oncol Biol Phys*. 2012;82(1):153-158.
  50. Franco P, Arcadipane F, Ragona R, et al. Locally advanced (T3-T4 or N+) anal cancer treated with simultaneous integrated boost radiotherapy and concurrent chemotherapy. *Anticancer Res*. 2016;36(4):2027-2032.
  51. Kachnic LA, Winter K, Myerson RJ, et al. RTOG 0529: a phase 2 evaluation of dose-painted intensity modulated radiation therapy in combination with 5-fluorouracil and mitomycin-C for the reduction of acute morbidity in carcinoma of the anal canal. *Int J Radiat Oncol Biol Phys*. 2013;86(1):27-33.
  52. Muirhead R, Adams RA, Gilbert DC, et al. National Guidance for IMRT in Anal Cancer. Version 4. 2016. Available at: <http://analimrtguidance.co.uk/National-Guidance-IMRT-Anal-Cancer-V4-Jan17.pdf>. Accessed July 2, 2021.
  53. Myerson RJ, Garofalo MC, El Naqa I, et al. Elective clinical target volumes for conformal therapy in anorectal cancer: a radiation therapy oncology group consensus panel contouring atlas. *Int J Radiat Oncol Biol Phys*. 2009;74(3):824-830.
  54. Gay HA, Barthold HJ, O'Meara E, et al. Pelvic normal tissue contouring guidelines for radiation therapy: a Radiation Therapy Oncology Group consensus panel atlas. *Int J Radiat Oncol Biol Phys*. 2012;83(3):e353-e362.
  55. Renehan AG, O'Dwyer ST. Initial management through the anal cancer multidisciplinary team meeting. *Colorectal Dis*. 2011;13(suppl 1):21-28.
  56. Downing A, Morris EJA, Aravani A, et al. The effect of the UK coordinating centre for cancer research anal cancer trial (ACT1) on population-based treatment and survival for squamous cell cancer of the anus. *Clin Oncol*. 2015;27(12):708-712.
  57. Renehan AG, Muirhead R, Sebag-Montefiore D. Limitations of the national cancer data base to evaluate early-stage anal cancer treatment outcomes. *JAMA Surgery*. 2018;153(7):691.
  58. Glynne-Jones R, Sebag-Montefiore D, Meadows HM, et al. Best time to assess complete clinical response after chemoradiotherapy in squamous cell carcinoma of the anus (ACT II): a post-hoc analysis of randomised controlled phase 3 trial. *Lancet Oncol*. 2017;18(3):347-356.
  59. Renehan AG, O'Dwyer ST. Management of local disease relapse. *Colorectal Dis*. 2011;13(suppl 1):44-52.
  60. Tan KK, Pal S, Lee PJ, et al. Pelvic exenteration for recurrent squamous cell carcinoma of the pelvic organs arising from the cloaca—a single institution's experience over 16 years. *Colorectal Dis*. 2013;15(10):1227-1231.
  61. Milne T, Solomon MJ, Lee P, et al. Sacral resection with pelvic exenteration for advanced primary and recurrent pelvic cancer: a single-institution experience of 100 sacrectomies. *Dis Colon Rectum*. 2014;57(10):1153-1161.
  62. Kontovounisios C, Tekkis P. Locally advanced disease and pelvic exenterations. *Clin Colon Rectal Surg*. 2017;30(5):404-414.
  63. Renehan AG, Saunders MP, Schofield PF, et al. Patterns of local disease failure and outcome after salvage surgery in patients with anal cancer. *Br J Surg*. 2005;92(5):605-614.
  64. Faivre C, Rougier P, Ducreux M, et al. 5-fluorouracil and cisplatin combination chemotherapy for metastatic squamous-cell anal cancer. *Bull Cancer*. 1999;86(10):861-865.
  65. Jaiyesimi IA, Pazdur R. Cisplatin and 5-fluorouracil as salvage therapy for recurrent metastatic squamous cell carcinoma of the anal canal. *Am J Clin Oncol*. 1993;16(6):536-540.
  66. Eng C, Chang GJ, You YN, et al. The role of systemic chemotherapy and multidisciplinary management in improving the overall survival of patients with metastatic squamous cell carcinoma of the anal canal. *Oncotarget*. 2014;5(22):11133-11142.
  67. Kim R, Byer J, Fulp WJ, et al. Carboplatin and paclitaxel treatment is effective in advanced anal cancer. *Oncology*. 2014;87(2):125-132.
  68. Kim S, Jary M, Mansi L, et al. DCF (docetaxel, cisplatin and 5-fluorouracil) chemotherapy is a promising treatment for recurrent advanced squamous cell anal carcinoma. *Ann Oncol*. 2013;24(12):3045-3050.
  69. Sclafani F, Morano F, Cunningham D, et al. Platinum-fluoropyrimidine and paclitaxel-based chemotherapy in the treatment of advanced anal cancer patients. *Oncologist*. 2017;22(4):402-408.
  70. Kim S, Francois E, Andre T, et al. Docetaxel, cisplatin, and fluorouracil chemotherapy for metastatic or unresectable locally recurrent anal squamous cell carcinoma (Epitopes-HPV02): a multicentre, single-arm, phase 2 study. *Lancet Oncol*. 2018;19(8):1094-1106.
  71. Rao S, Sclafani F, Eng C, et al. International Rare Cancers Initiative multicenter randomized phase II trial of cisplatin and fluorouracil versus carboplatin and paclitaxel in advanced anal cancer: InterAACT. *J Clin Oncol*. 2020;38(22):2510-2518.
  72. Ott PA, Elez E, Hirt S, et al. Pembrolizumab in patients with extensive-stage small-cell lung cancer: results from the phase Ib KEYNOTE-028 study. *J Clin Oncol*. 2017;35(34):3823-3829.
  73. Morris VK, Salem ME, Nimeiri H, et al. Nivolumab for previously treated unresectable metastatic anal cancer (NCI9673): a multicentre, single-arm, phase 2 study. *Lancet Oncol*. 2017;18(4):446-453.
  74. Sclafani F, Rao S. Systemic therapies for advanced squamous cell anal cancer. *Curr Oncol Rep*. 2018;20(7):53.
  75. Bentzen AG, Guren MG, Vonen B, et al. Faecal incontinence after chemoradiotherapy in anal cancer survivors: long-term results of a national cohort. *Radiother Oncol*. 2013;108(1):55-60.
  76. Bentzen AG, Balteskard L, Wanderas EH, et al. Impaired health-related quality of life after chemoradiotherapy for anal cancer: late effects in a national cohort of 128 survivors. *Acta Oncol*. 2013;52(4):736-744.
  77. Sodergren SC, Vassiliou V, Dennis K, et al. Systematic review of the quality of life issues associated with anal cancer and its treatment with radiochemotherapy. *Support Care Cancer*. 2015;23(12):3613-3623.
  78. Olsen JR, Moughan J, Myerson R, et al. Predictors of radiation therapy-related gastrointestinal toxicity from anal cancer dose-painted intensity modulated radiation therapy: secondary analysis of NRG oncology RTOG 0529. *Int J Radiat Oncol Biol Phys*. 2017;98(2):400-408.
  79. Fish R, Sanders C, Adams R, et al. A core outcome set for clinical trials of chemoradiotherapy interventions for anal cancer (CORMAC): a

- patient and health-care professional consensus. *Lancet Gastroenterol Hepatol*. 2018;3(12):865-873.
80. Sodergren SC, Johnson CD, Gilbert A, et al. Phase I-III development of the EORTC QLQ-ANL27, a health-related quality of life questionnaire for anal cancer. *Radiother Oncol*. 2018;126(2):222-228.
81. Dykewicz CA. Summary of the guidelines for preventing opportunistic infections among hematopoietic stem cell transplant recipients. *Clin Infect Dis*. 2001;33(2):139-144 (adapted from: Gross PA, Barrett TL, Dellinger EP, et al. Purpose of quality standards for infectious diseases. *Clin Infect Dis*.1994;1918:1421).